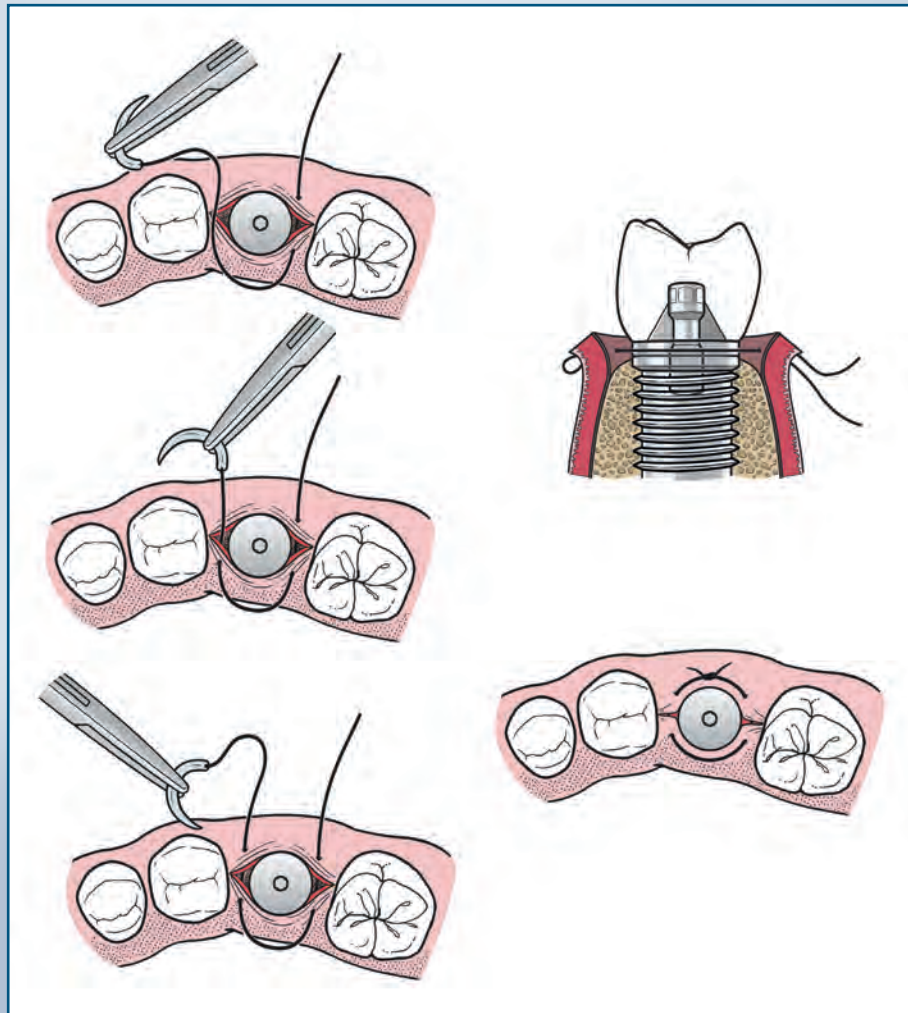




*Journal of*  
**ORAL AND  
MAXILLOFACIAL SURGERY**

**GUIDE TO SUTURING**  
with Sections on Diagnosing Oral Lesions and  
Post-Operative Medications





# Journal of Oral and Maxillofacial Surgery

## Subscriptions:

Yearly subscription rates: United States and possessions: individual, \$330.00 student and resident, \$221.00; single issue, \$56.00. Outside USA: individual, \$518.00; student and resident, \$301.00; single issue, \$56.00. To receive student/resident rate, orders must be accompanied by name of affiliated institution, date of term, and the *signature* of program/residency coordinator on institution letterhead. Orders will be billed at individual rate until proof of status is received. Prices are subject to change without notice. Current prices are in effect for back volumes and back issues. Single issues, both current and back, exist in limited quantities and are offered for sale subject to availability. Back issues sold in conjunction with a subscription are on a prorated basis. Correspondence regarding subscriptions or changes of address should be directed to **JOURNAL OF ORAL AND MAXILLOFACIAL SURGERY**, Elsevier Health Sciences Division, Subscription Customer Service, 3251 Riverport Lane, Maryland Heights, MO 63043. Telephone: 1-800-654-2452 (US and Canada); 314-447-8871 (outside US and Canada). Fax: 314-447-8029. E-mail: [journalscustomerservice-usa@elsevier.com](mailto:journalscustomerservice-usa@elsevier.com) (for print support); [journalsonline-support-usa@elsevier.com](mailto:journalsonline-support-usa@elsevier.com) (for online support). Changes of address should be sent preferably 60 days before the new address will become effective. Missing issues will be replaced free of charge if the publisher is notified at the above address within 2 months of publication of the issue for US subscribers and within 4 months for subscribers from all other countries.

## Editorial:

Editorial correspondence and manuscripts should be submitted online at <http://ees.elsevier.com/joms/>. The Notice to Contributors, which lists manuscript requirements in more detail, is available on the *Journal's* website, [www.joms.org/authorinfo](http://www.joms.org/authorinfo).

## Permissions:

Permissions may be sought directly from Elsevier's Global Rights Department in Oxford, UK; phone: (215) 239-3804 or +44 (0) 1865 843830, fax: +44 (0) 1865 853333. Requests may also be completed online via the Elsevier homepage (<http://www.elsevier.com/authors/obtaining-permission-to-re-use-elsevier-material>).

## Copyright:

Copyright © 2015 by the American Association of Oral and Maxillofacial Surgeons. All rights reserved. No part of this publication may be reproduced or transmitted in any form or by any means, now or hereafter known, electronic or mechanical, including photocopying, recording, or any information storage and retrieval system, without permission in writing of the publisher. Printed in the United States of America.

The appearance of the code at the bottom of the first page of an article in this journal indicates the copyright owner's consent that copies of the article may be made for personal or internal use, or for the personal or internal use of specific clients, for those registered with the Copyright Clearance Center, Inc. (222 Rosewood Drive, Danvers, MA 01923; 1-978-750-8400; [www.copyright.com](http://www.copyright.com)). This consent is given on the condition that the copier pay the stated per-copy fee for that article through the Copyright Clearance Center, Inc. for copying beyond that permitted by Sections 107 or 108 of the US Copyright Law. This consent does not extend to other kinds of copying, such as copying for general distribution, for advertising or promotional purposes, for creating new collective works, or for resale. Absence of the code indicates that the material may not be processed through the Copyright Clearance Center, Inc.

## Reprints:

For 100 or more copies of an article in this publication, please contact Derrick Imasa at 212-633-3874, Elsevier Inc., 360 Park Ave South, New York, NY 10010-1710. Fax: 212-462-1935; e-mail: [reprints@elsevier.com](mailto:reprints@elsevier.com). Reprints of single articles available online may be obtained by purchasing Pay-Per-View access for \$30 per article on the *Journal's* website, [www.joms.org](http://www.joms.org).

## Advertising:

For information concerning placement of commercial advertising, please contact Joan Coffey at Elsevier, 360 Park Avenue South, New York, NY 10010. Tel: (212) 633-3806; fax: (212) 633-3820. For information concerning placement of classified advertising, please contact Ariel Medina at Elsevier, 360 Park Avenue South, New York, NY 10010. Tel: (212) 633-3689; fax: (212) 633-3820. Advertising guidelines are available upon request.

## Journal of Oral and Maxillofacial Surgery:

is covered in Index Medicus, Current Contents/Clinical Medicine, Science Citation Index, ASCA (Automatic Subject Citation Alert), ISI/Biomed, Cinahl, the Index to Dental Literature, and the Hospital Literature Index.



# Journal of Oral and Maxillofacial Surgery

<b>Editor-in-Chief</b>	James R. Hupp	
<b>Editors Emeriti</b>	Daniel M. Laskin Leon A. Assael	
<b>Associate Editor</b>	Thomas B. Dodson	
<b>Section Editors</b>	<p>John H. Campbell <i>Dentoalveolar Surgery</i></p> <p>Michael S. Block <i>Implants</i></p> <p>Edward Ellis III <i>Craniomaxillofacial Trauma</i></p> <p>Eric R. Carlson <i>Surgical Oncology and Reconstruction</i></p>	<p>Jeffrey D. Bennett <i>Anesthesia/Facial Pain</i></p> <p>M. Anthony Pogrel <i>Pathology</i></p> <p>Michael Miloro <i>Craniomaxillofacial Deformities/ Cosmetic Surgery</i></p> <p>Janie Dunham <i>News</i></p>
<b>Editorial Board</b>	<p>Shahrokh C. Bagheri Scott B. Boyd Stephanie J. Drew Elie M. Ferneini David E. Frost Leonard B. Kaban</p>	<p>J. Michael McCoy Samuel J. McKenna David H. Perrott Faisal A. Quereshy C. Randolph Todd Trevor E. Treasure Brent B. Ward</p>
<b>International Editorial Board</b>	<p>Asri Arumsari - <i>Indonesia</i> Peter Brennan - <i>United Kingdom</i> Nardy Casap - <i>Israel</i> Lim Kwong Cheung - <i>Hong Kong</i> Ann C. Collins - <i>Australia</i> Kyung-Wook Kim - <i>Korea</i> Reha Kisnisci - <i>Turkey</i> Mohammad H.K. Motamedi - <i>Iran</i></p>	<p>Kenichiro Murakami - <i>Japan</i> Alexander D. Rapidis - <i>Greece</i> George K. B. Sándor - <i>Finland</i> Darryl Tong - <i>New Zealand</i> Corrado Toro - <i>Italy</i> Jia Wei Zheng - <i>China</i></p>
<b>Continuing Education</b>	Charles N. Bertolami	
<b>Statistical Reviewer</b>	Sung-Kiang Chuang	
<b>Managing Editor</b>	Carmen E. Hupp	
<b>Publisher</b>	Elizabeth Perill	Michele Willmunder <i>Journal Manager</i>

www.joms.org

*Journal of*  
**ORAL AND  
MAXILLOFACIAL SURGERY**

August 2015 • Volume 73 • Supplement 1

**GUIDE TO SUTURING**  
**with Sections on Diagnosing Oral Lesions  
and Post-Operative Medications**

**Editor: James R. Hupp, DMD, MD, JD**



Saving Faces | Changing Lives®

*Official Journal of the  
American Association of  
Oral and Maxillofacial Surgeons*



## AAOMS BOARD OF TRUSTEES

### Officers

William J. Nelson, DDS  
President

Louis K. Rafetto, DMD  
President-Elect

Douglas W. Fain DDS, MD, FACS  
Vice President

Brett L. Ferguson, DDS  
Treasurer

Eric T. Geist, DDS  
Immediate Past President

Robert C. Rinaldi, PhD, CAE  
Executive Director

Steven R. Nelson, DDS, MS  
Speaker, House of Delegates

### Trustees

Victor L. Nannini, DDS  
Trustee, District I  
*(Northeastern)*

Vincent E. DiFabio, DDS, MS  
Trustee, District II  
*(Middle Atlantic)*

J. David Johnson, Jr., DDS  
Trustee, District III  
*(Southeastern)*

Paul M. Lambert, DDS  
Trustee, District IV  
*(Great Lakes)*

B.D. Tiner, DDS, MD, FACS  
Trustee, District V  
*(Midwestern)*

A. Thomas Indresano, DMD  
Trustee, District VI  
*(Western)*

## CONTRIBUTORS TO GUIDE TO SUTURING:

### Sections I, II and IV

James R. Hupp,<sup>1</sup> DMD, MD, JD

### Section III

Edward Ellis III,<sup>2</sup> DDS, MS  
James R. Hupp,<sup>1</sup> DMD, MD, JD

<sup>1</sup> Founding Dean and Professor of Oral-Maxillofacial Surgery  
School of Dental Medicine, East Carolina University

<sup>2</sup> Professor and Department Chair, Oral and Maxillofacial Surgery,  
School of Dentistry, University of Texas Health Science Center San Antonio



# Journal of Oral and Maxillofacial Surgery

VOLUME 73, SUPPLEMENT 1, AUGUST 2015

## Guide to Suturing

- 1 Letter of Welcome  
*William J. Nelson*

## Section I

- 2 Introduction

## Section II

- 3 Oral Surgery Suturing
- 4 Introduction to Suturing
- 6 Instrumentation
- 17 Suturing Techniques

## Section III

- 30 Surgical Pathology

## Section IV

- 57 Postoperative Medications

---

Except where specifically stated, the opinions expressed or statements made in articles or editorials are not endorsed by nor represent official policy of the American Association of Oral and Maxillofacial Surgeons or the publisher, Elsevier. Publication of an advertisement in this journal does not imply endorsement of the product or service by the American Association of Oral and Maxillofacial Surgeons or Elsevier. Conflict of Interest Disclosures: None of the authors reported any disclosures.



## Letter of Welcome

Congratulations. As a future dentist, you will soon embark on an exciting career that offers unlimited opportunities for personal growth and improving the oral health and lives of your patients. As you advance through your dental school curriculum, you will learn more about the nine ADA-recognized dental specialties and the skills and unique training that set them apart from general dentistry and each other.

Whether you decide to practice general dentistry or pursue a dental specialty, you will from time to time be required to suture a wound or surgical incision in the oral cavity. Successful suturing techniques require careful attention to both function and esthetic concerns.

The American Association of Oral and Maxillofacial Surgeons (AAOMS) believes it is vital that the dentist placing a suture is trained in the proper technique, the use of appropriate materials, and the potential consequences of an improperly placed suture. We are pleased to present you with this *Guide to Suturing* to assist you in perfecting your suturing skills. We have also included information on biopsy techniques and prescription medication ordering that we trust you will find useful as you provide care for your patients in dental school and in the future.

The AAOMS is the professional association that represents the more than 9,000 oral and maxillofacial surgeons practicing in the United States. As the surgical specialists of the dental profession, oral and maxillofacial surgeons are the experts in face, mouth, and jaw surgery.

Oral and maxillofacial surgeons enjoy a far-reaching scope of practice that includes dentoalveolar and implant surgery, anesthesiology, management of facial injuries and deformities, treatment of oral, head, and neck cancer, and reconstructive and cosmetic surgery. It is an exciting surgical specialty that is both challenging and rewarding. As you consider your future in dentistry, I invite you to learn more about the specialty of oral and maxillofacial surgery by visiting our Web site at [AAOMS.org](http://AAOMS.org) and our new patient site at [MyOMS.org](http://MyOMS.org).

Sincerely,



William J. Nelson, DDS  
President, American Association of Oral and Maxillofacial Surgeons

## Section I Introduction

The field of oral and maxillofacial surgery has a broad scope, and specialists in this field provide a wide array of services to patients with problems that range from dental infections to head and neck malignancies. Oral and maxillofacial surgeons remove impacted teeth, place implants, perform procedures to correct cleft and other dentofacial deformities, fix hard and soft tissue injuries to the face and jaws, and manage complex oral and facial pathology, including reconstruction of the resulting deformity, among many other services. Oral and maxillofacial surgeons regularly partner with general dentists to help provide specialty care for their patients.

There are oral surgical procedures that are part of the broad scope of general dentistry. These include routine oral surgery such as the extraction of teeth, suturing wounds, and biopsying suspicious soft tissue lesions. Oral and maxillofacial surgery textbooks provide didactic guidance to help dental students learn these skills. However, it is cumbersome to bring textbooks into dental school preclinical learning suites or actual clinical settings, and even more difficult for students who receive their textbooks electronically. Focused guides are better suited for serving as a laboratory or clinical resource when learning and mastering surgical skills. This is why this guide was developed.

Suturing a wound is fun and satisfying to perform. However, learning the various suturing techniques can be a trying experience. Suturing in the mouth further complicates the situation. Section II attempts to unravel the mystery of placing and tying sutures. The key instruments and materials used for intraoral suturing are presented. A detailed description and heavily illustrated guide to suturing follows.

Section III addresses the topic of diagnostic pathology, providing a well-reasoned approach to describing and differentiating oral lesions. A discussion of various biopsy techniques is then given to help the student be able to surgically sample oral soft tissue, when indicated, and then submit the sample for examination by an oral and maxillofacial pathologist.

Section IV provides guidance on prescription writing. A succinct discussion follows of analgesics and antibiotics commonly used for the oral surgery patient. Just as with any of the skills needed to become a well-trained general dentist, learning under the close guidance of expert faculty is required. This manual is intended to complement faculty instruction. Also, just as with many of the surgical skills dentists acquire, there is an aspect of art in their performance. Therefore, individual faculty might share or prefer variations on the concepts presented in the following pages.



## Section II Oral Surgery Suturing

The ability to suture is one of the essential skills required of anyone planning to perform surgery. Although it can appear to be a simple procedure, suturing properly requires a sound understanding of the biology of wound healing, good hand-eye coordination, good judgment, and some finesse. Learning to suture in an expert manner requires an understanding of the proper techniques and dedicated practice.

This section on suturing in this special student supplement is designed to guide dental students as they learn and master the suturing techniques most commonly used to close oral mucosa. Most of the techniques covered are also used in surgery performed elsewhere in the body.

The suture section presumes that the student already possesses an understanding of the basic anatomy and physiology of oral tissues and basic knowledge in soft tissue wound healing.

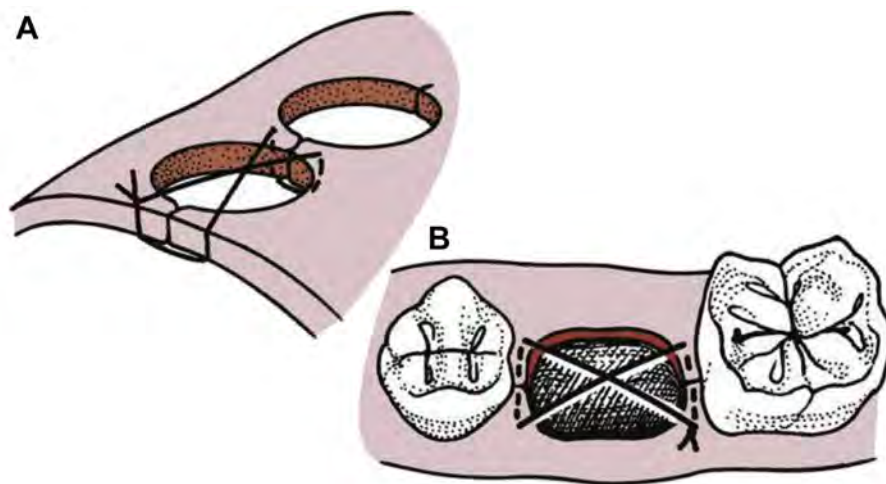
This special supplement is not intended to serve as a self-instructional manual. Rather, it is meant to complement the teaching of dental school faculty. Just as with any skill requiring manual actions, learning the various suturing techniques is most effective and efficient when done under the careful supervision of educators who can provide needed demonstrations and coaching.

## Section IIA Introduction to Suturing

Once a surgical procedure is completed and the wound properly irrigated and debrided, the surgeon should return elevated or incised tissue to its original position or, if necessary, place it in a new position, and hold it in place with sutures.

Sutures perform multiple functions. The most obvious and important function that sutures perform is to coapt wound margins; that is, to hold the tissue in position and approximate the opposing wound edges. The sharper the incision and less trauma inflicted on the wound margin, the more probable is healing by primary intention. If the space between the 2 wound edges is minimal, wound healing will be rapid and complete. If tears or excessive trauma to the wound edges occur, wound healing might need to occur by secondary intention. Thus, when suturing a flap back into position or closing a biopsy site, the surgeon will usually attempt to use sutures to bring the wound edges into close contact. However, in cases in which healing by secondary intention is planned, such as after the extraction of an erupted tooth, sutures are only used to reapproximate any papillae that were elevated.

Sutures can also aid in hemostasis. When a flap has been used to gain access, suturing it back into position helps stop bleeding. If the underlying tissue is bleeding significantly, the surface mucosa or skin should not be closed, because the bleeding in the underlying tissue could continue and result in the formation of a hematoma. In such cases, better hemostasis should be achieved before wound closure. Similarly, overlying soft tissue should never be sutured tightly in an attempt to gain hemostasis of a bleeding tooth socket. Instead, direct pressure should be applied. Sutures can be used as an aid in maintaining a blood clot in the alveolar socket. A special suture, such as a figure-of-eight suture, can provide a barrier to clot displacement (Fig II-1). However, it should be emphasized that suturing across an open wound socket plays a minor role in maintaining the blood clot in the tooth socket. However, the figure-of-eight suture can help retain procoagulant or other materials placed into a socket. (The figure-of-eight suture is further discussed in Section II-C.)



**FIGURE II-1.** A, The figure-of-eight suture, occasionally placed over the top of the socket to aid in hemostasis. B, This suture can be used to hold elevated papillae back into proper position and to help maintain oxidized cellulose placed in a tooth socket to promote coagulation. Reprinted with permission from Hupp<sup>1</sup>.

Sutures help hold a soft tissue flap over bone. This is an important function because bone that is not covered with soft tissue becomes nonvital and requires an excessively long time to heal. When mucoperiosteal flaps are reflected from alveolar bone, it is important that the extent of the bone be recovered with soft tissue flaps. Unless appropriate suture techniques are used, the flap can retract away from bone, which exposes it and results in delayed healing.

The surgeon must remember that the purpose of the suture is merely to reapproximate the tissue; therefore, the suture should not be tied too tightly. Sutures that are too tight will cause ischemia of the flap margin and result in tissue necrosis, with eventual tearing of the suture through the tissue. Thus, sutures that are too tightly tied will result in wound dehiscence more frequently than sutures that are loosely tied. As a clinical guideline, no blanching or obvious ischemia of the wound edges should be present. If this occurs, the suture should be removed and replaced. The knot should be positioned so that it does not fall directly over the incision line, because this causes additional pressure on the wound. Therefore, the knot should be positioned to the side of the incision line.

## Reference

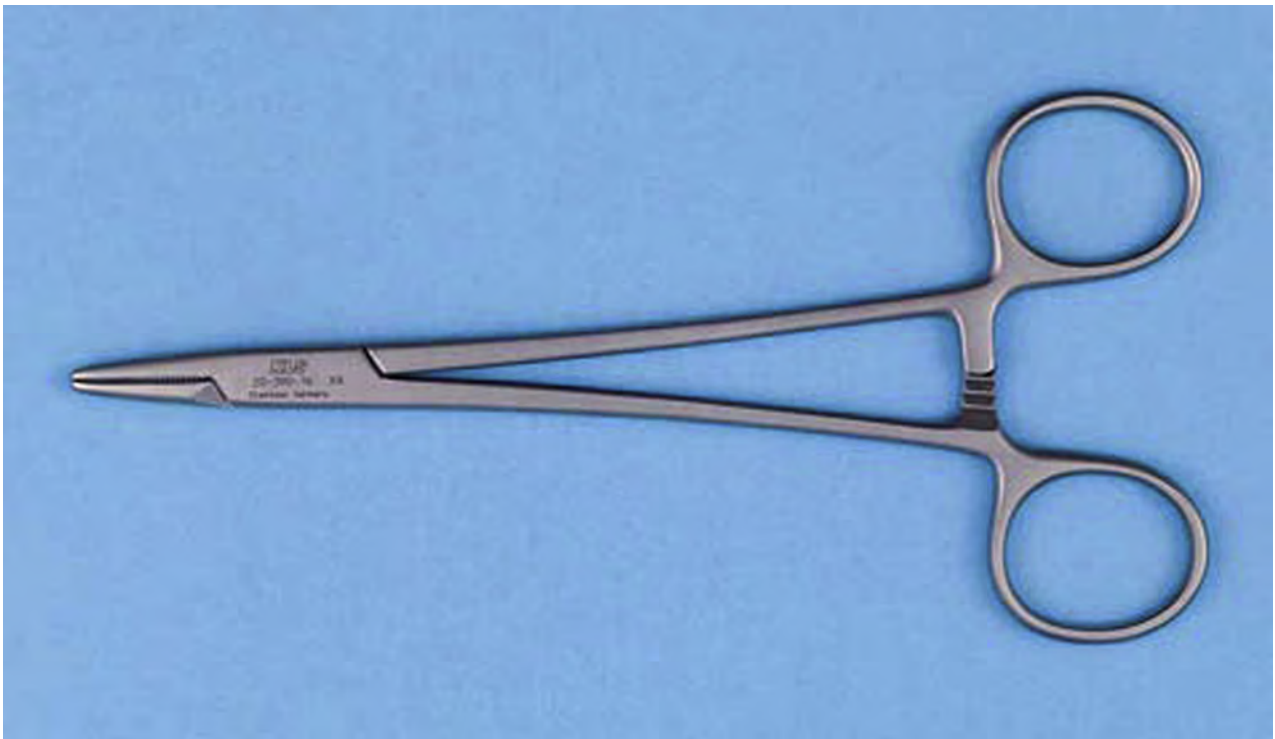1. Hupp JR, Ellis III E, Tucker MR: Contemporary Oral And Maxillofacial Surgery (ed 6). St. Louis, MO, Elsevier, 2014

## Section IIB Instrumentation

Routine extraction of a tooth does not automatically create the need to place sutures. However, if interdental papillae have been cut or inadvertently torn, or a flap has been raised, suturing is usually indicated. This section will discuss the instruments and materials used for suturing in the oral cavity.

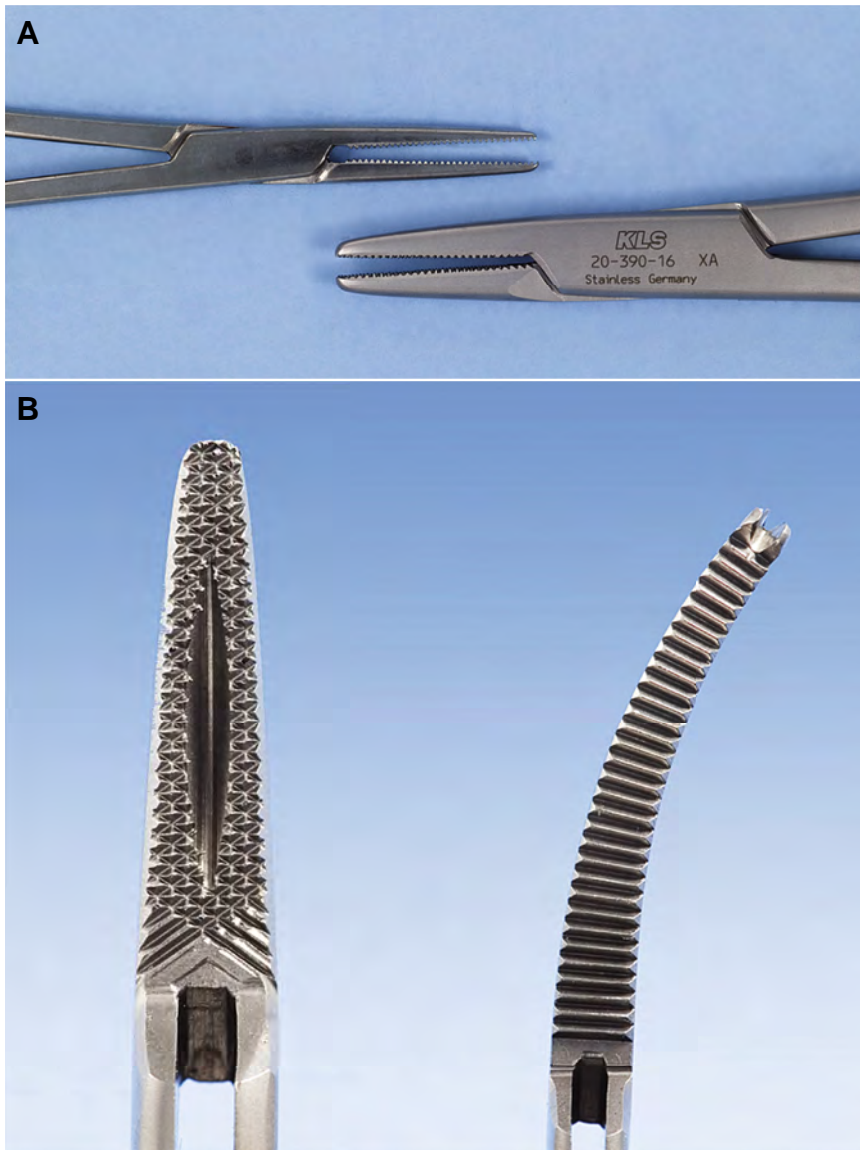
### Needle Holder

The needle holder is an instrument with a locking handle and a short, blunt beak. For intraoral placement of intraoral sutures, a 6-in. (15-cm) needle holder is usually recommended (Fig II-2). The beaks of a needle holder are shorter and stronger than the beaks of a hemostat, an instrument not designed to hold a suture needle. The face of a beak of the needle holder is cross-hatched to permit a positive grasp of the suture needle. The hemostat has parallel grooves on the face of the beaks, thereby decreasing the control over the needle and suture. Therefore, the hemostat is not used for suturing (Fig II-3).



print & web 4C/FPO

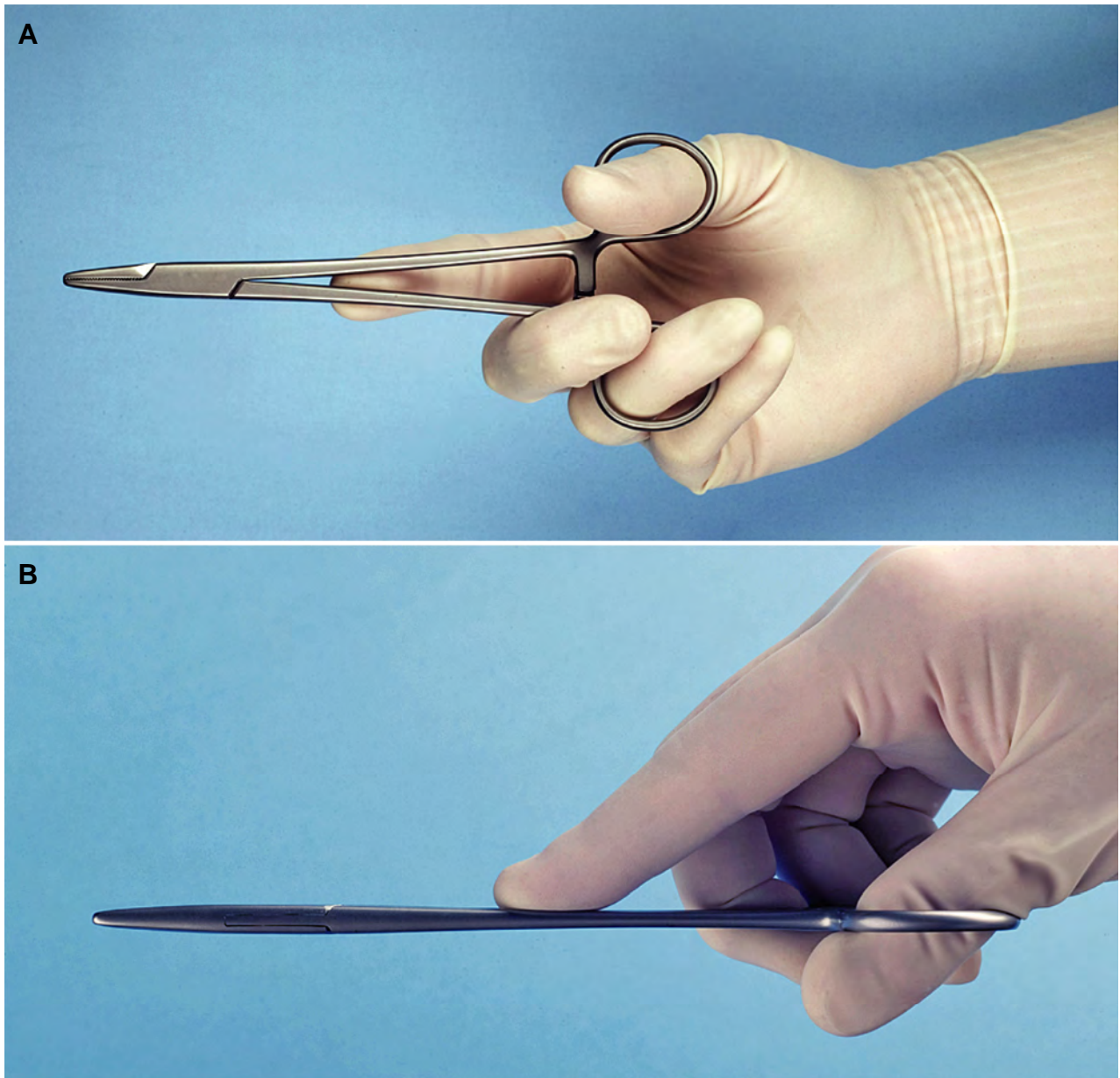
**FIGURE II-2.** A needle holder has a locking handle and a short, stout beak. Reprinted with permission from Hupp<sup>1</sup>.



print &amp; web 4C/FPO

**FIGURE II-3.** A, A hemostat (*Top*) has a longer, thinner beak compared with the needle holder (*Bottom*) and, therefore, should not be used for suturing. B, The faces of the beaks of the needle holder are cross-hatched to ensure a positive grip on the needle (*Left*). The faces of the hemostat have parallel grooves that do not allow a firm grip on the needle (*Right*). Reprinted with permission from Hupp<sup>1</sup>.

To control the locking handles of the needle holder properly and to direct the beaks of the needle holder, the surgeon must hold the instrument properly (Fig II-4). The thumb and ring finger are inserted through the rings. The index finger is held along the length of the needle holder to steady and direct it. The second finger aids in controlling the locking mechanism. The index finger should not be put through the finger ring, because this will result in a dramatic decrease in control.



print & web 4C/FPO

**FIGURE II-4.** A, The needle holder is held using the thumb and ring finger in the rings, allowing them to open and close and unlock the needle holder. B, The first and second fingers help direct the instrument. Reprinted with permission from Hupp<sup>1</sup>.



## Tissue Forceps

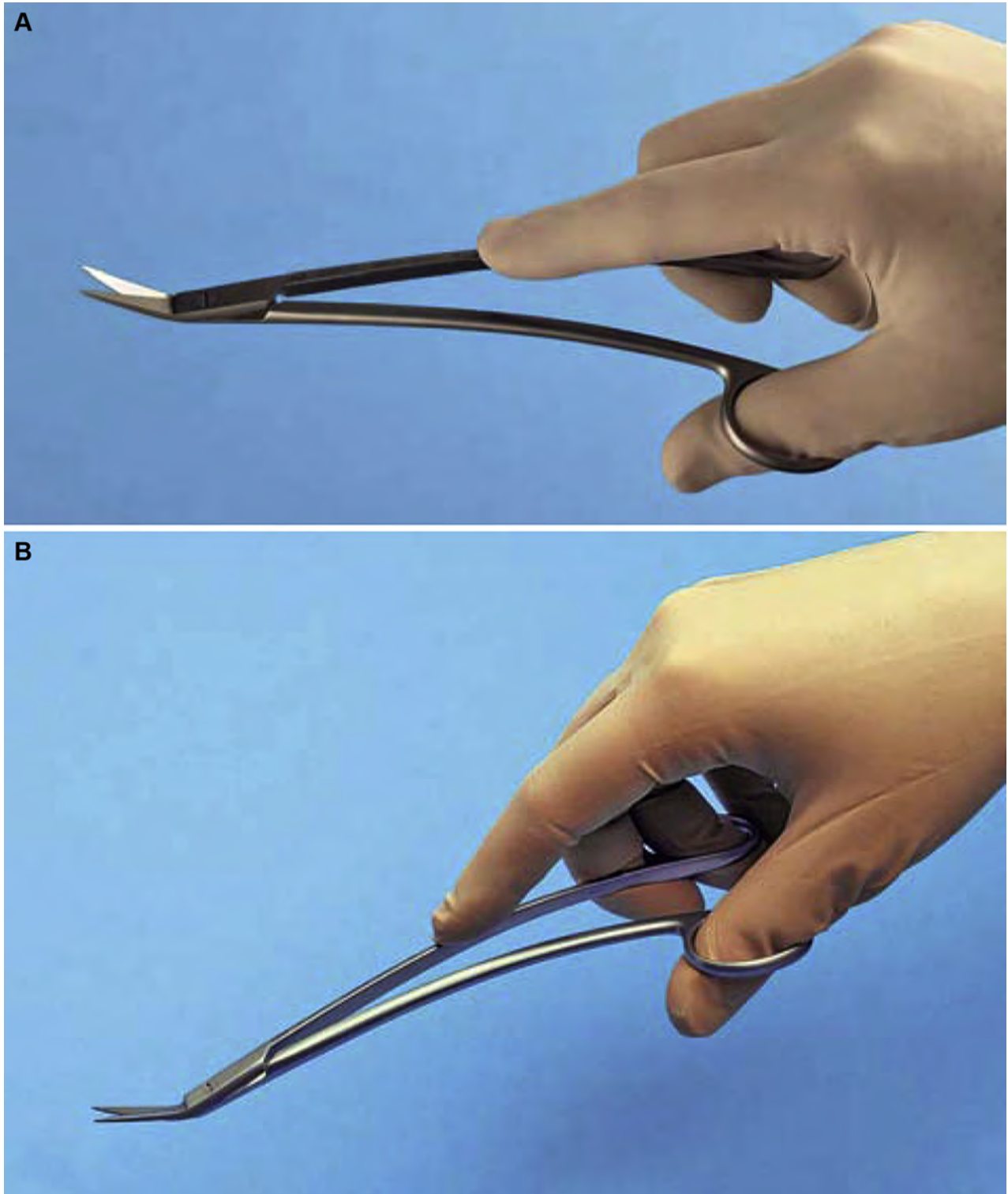
Many surgeons prefer to grasp soft tissue with an instrument while suturing. The tissue forceps commonly used for this purpose for dentoalveolar suturing are the Adson forceps (or pickups; Fig II-5). These are delicate forceps, with or without small teeth at the tips, which can be used to hold tissue gently and thereby stabilize it. When this instrument is used, care should be taken not to grasp the tissue too tightly, crushing the tissue. Toothed forceps allow tissue to be held with a more delicate grip than untoothed forceps. Adson forceps are also commonly used when performing a biopsy (see Section II). Learning how to suture is challenging; thus, illustrations do not show the use of tissue forceps while suturing. This approach to suturing is better demonstrated by an instructor.



**FIGURE II-5.** A, Adson forceps (pickups) with teeth. The small, delicate toothed type of Adson forceps can be used to gently, but securely, grasp soft tissue while placing sutures or dissecting. B, Close-up view shows the fine teeth of forceps. Adson forceps also come without teeth (not shown). B, Reprinted with permission from Hupp<sup>1</sup>.

## Scissors

The final instruments necessary for placing sutures are suture scissors (Fig II-6). Suture scissors usually have short cutting edges because their sole purpose is to cut sutures. The most commonly used suture scissors for oral surgery are Dean scissors. These scissors have slightly curved handles and offset serrated blades that make cutting sutures easier. Suture scissors usually have long handles and thumb and finger rings. The scissors are held in the same way as are needle holders.



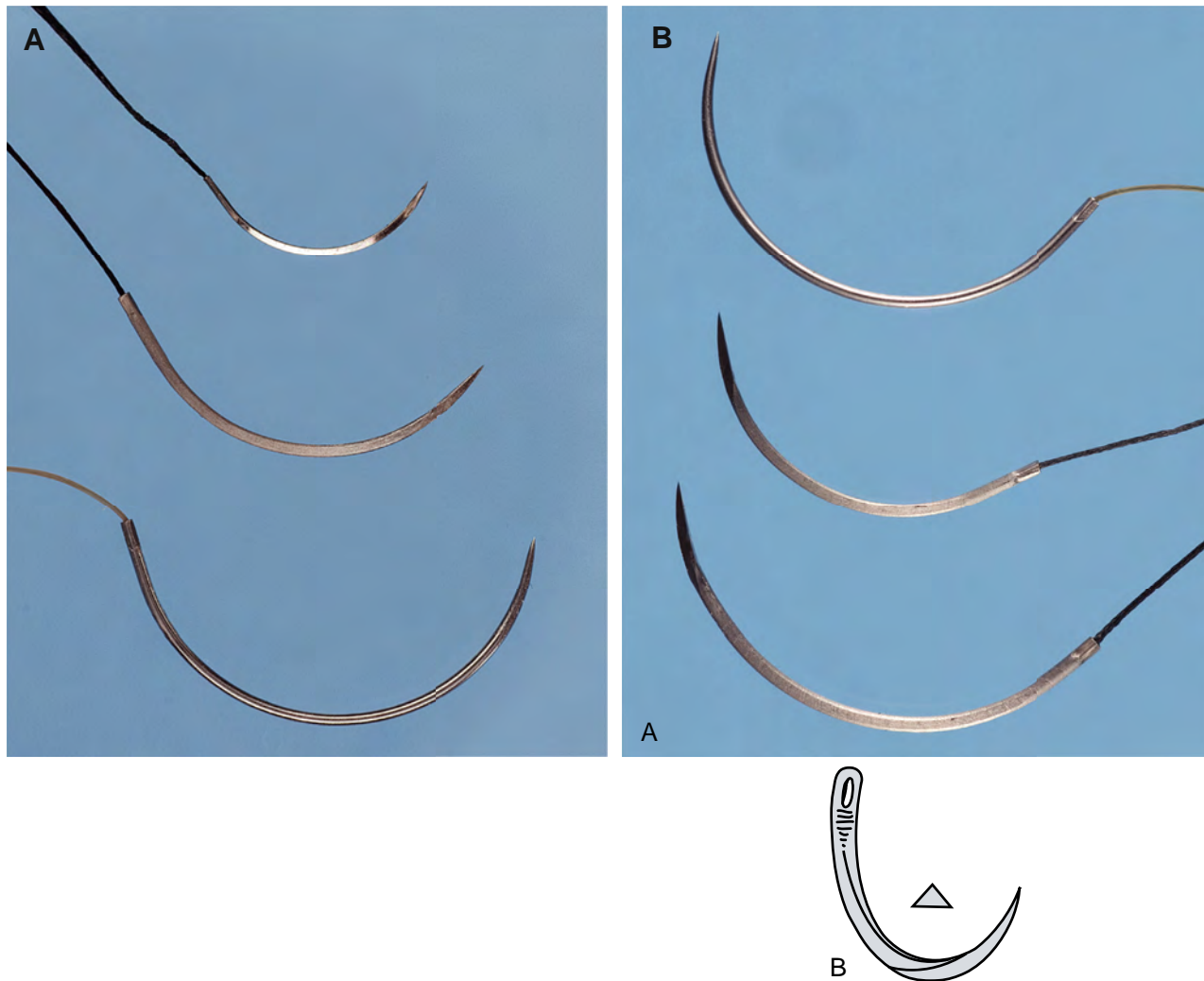
print & web 4C/FPO

**FIGURE II-6.** A, B, Dean scissors are commonly used to cut sutures after tying the knot. The suture scissors should be held in the same fashion as the needle holder. Reprinted with permission from Hupp<sup>1</sup>.

## Suture Needle

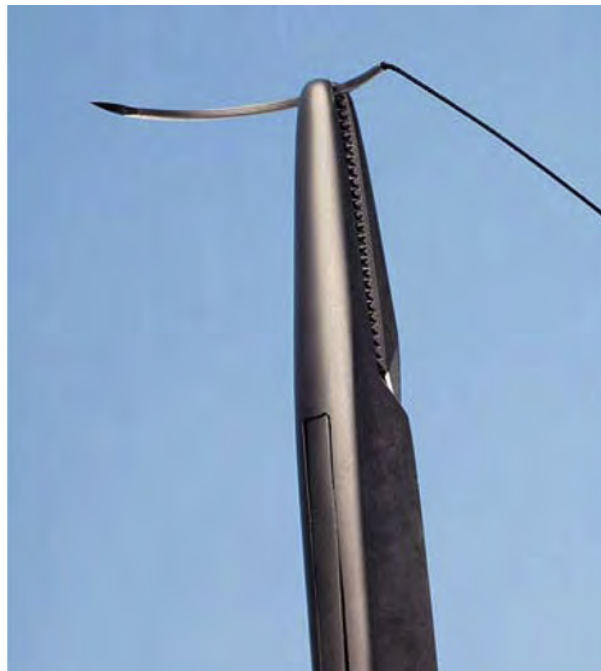
Suture needles come in a large variety of shapes, from very small to very large (Fig II-7A). The needle used in closing oral mucosal incisions is usually a small half-circle or three-eighths-circle suture needle. The needle is curved to allow it to pass through a limited space that a straight needle cannot reach, and passage can be done with rotation of the wrist.

The tips of suture needles either are tapered similar to sewing needles or have triangular tips that allow them to be cutting needles. A cutting needle will pass through the mucoperiosteum more easily than a tapered needle (Fig II-7B). The cutting portion of the needle extends about one third the length of the needle, and the remaining portion of the needle is rounded. Tapered needles are used for more delicate tissues, such as in ocular or vascular surgery. Care must be taken with cutting needles, because they can cut through tissue lateral to the track of the needle if not used carefully or correctly. The suture material is usually purchased already swaged on (a means of fusing the end of a suture onto a needle) by the manufacturer.



**FIGURE II-7.** A, The shapes and types of needles commonly used in oral surgery are the three-eighths-circle (*Top and Middle*) and half-circle (*Bottom*) cutting needles. *Top*, PS-2; *Middle*, FS-2; *Lower*, X-1. Notice how the suture is securely swaged (press-fitted) onto the needle. B, Drawing of a cutting needle with a triangular cross-section. This allows the needle to glide through tissue such as gingiva more readily than a tapered (noncutting) needle. Reprinted with permission from Hupp<sup>1</sup>.

The curved needle is held approximately two thirds of the distance between the tip and the base of the needle (Fig II-8). This allows enough of the needle to be exposed to pass through the tissue while allowing the needle holder to grasp the needle in its strong portion to prevent bending of the needle or dulling of the tip.



print & web 4C/FPO

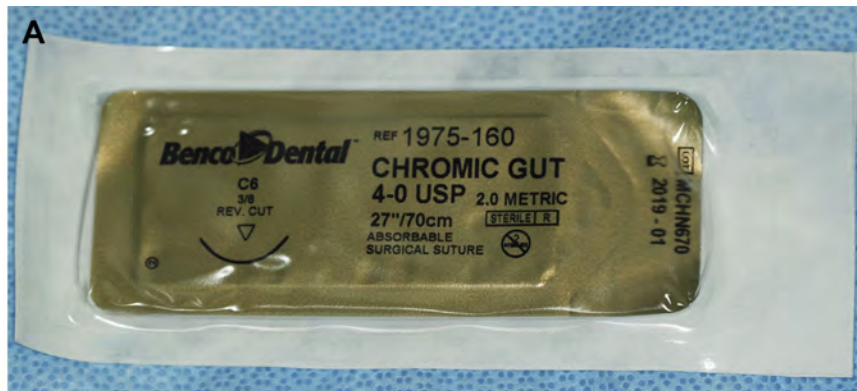
**FIGURE II-8.** The needle holder grasps the curved needle about two thirds of the distance away from the tip of the needle (termed “loading the needle holder”). This usually allows enough of the needle to pass through tissue so that the surgeon can regrasp the needle below the tip. The needle should be held in the tips of the beaks of the needle holder for best control. Reprinted with permission from Hupp<sup>1</sup>.



## Suture Material

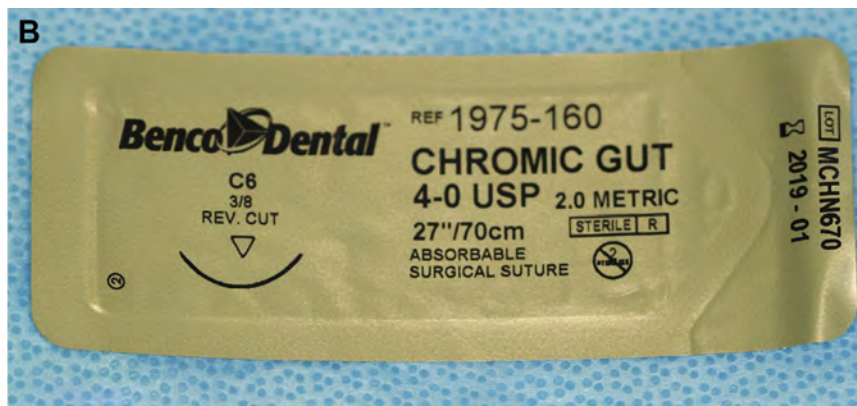
Many types of suture materials are available. The materials are classified by diameter, resorbability, and filament type (monofilament or polyfilament).

The size of a suture relates to its diameter and is designated by a series of zeros. The diameter most commonly used in the suturing of oral mucosa is 3-0 (000). A larger size suture is 2-0, or 0. Smaller sizes are designated with more zeros, for example 4-0, 5-0, and 6-0. Sutures of very fine size, such as 6-0, are usually used in conspicuous places on the skin; for example, the face, because properly placed smaller sutures usually cause less scarring. Sutures of size 3-0 are large enough to withstand the tension placed on them intraorally and strong enough for easier knot tying with a needle holder than smaller diameter sutures (Fig II-9A to E).



print & web 4C/FPO


**FIGURE II-9A.** Surgical sutures come double-wrapped. This allows the nonsterile outer wrapper to be handled by unsterile hands. The outer packaging is designed so it can be peeled open, allowing the sterile inner pack to be dropped onto the sterile instrument tray or presented to someone with gloved hands to remove.



print & web 4C/FPO


**FIGURE II-9B.** The suture inner pack is labeled, describing the type and size of the suture and the type and shape of the needle swaged onto the suture. In this case, this is a 4-0 absorbable chromic gut suture with a 3/8 circular, reversed cutting needle (C6 is the generic name of such a needle). The term “reversed” means that the triangular cross-section of the cutting needle points downward. The suture is 27 in. or 70 cm long. The diagram on the package shows the actual shape and size of the needle in the pack.

print &amp; web 4C/FPO




**FIGURE II-9C.** The inner package is designed to be peeled open, exposing the contents. The contents will be moist in this case, because this is a chromic gut suture that must be kept moist to allow proper suture handling while placing and knotting the suture. The thin cardboard in the pack is labeled on one side to show the suture size and scored to show the location of the underlying needle.

print &amp; web 4C/FPO



**FIGURE II-9D.** Folding down the designated corner reveals the needle lying in its own compartment, separate from the suture. The needle is ready to be grasped by a needle holder.

print &amp; web 4C/FPO



**FIGURE II-9E.** Once the needle is grasped, the inner fold can be opened, revealing the suture carefully coiled to reduce the chance of tangling, as it is slowly unfurled.



Sutures can be resorbable or nonresorbable. Nonresorbable suture materials include such types as silk, nylon, vinyl, and stainless steel. The most commonly used nonresorbable suture in the oral cavity is silk. Nylon, vinyl, and stainless steel are rarely used in the mouth.

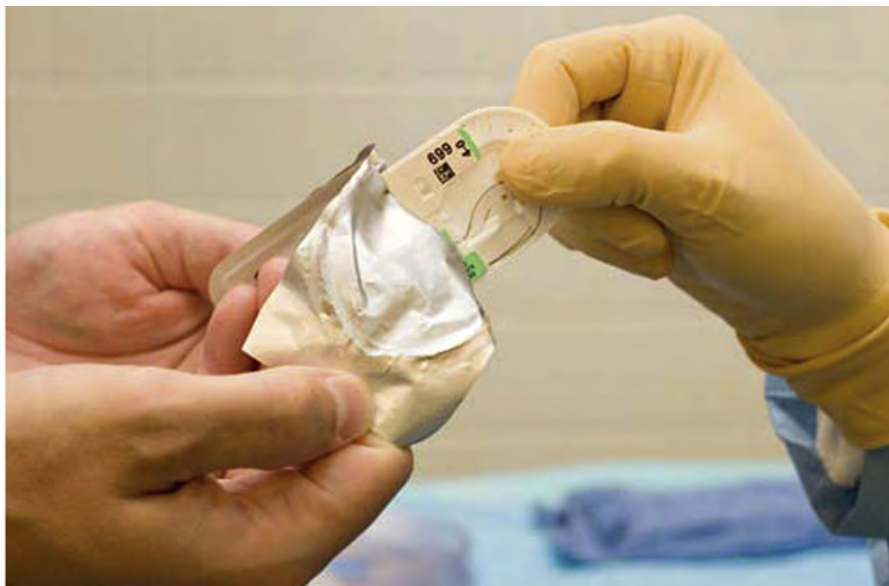Resorbable sutures are primarily made of gut. Although the term “catgut” is often used to designate this type of suture, the gut actually is derived from the serosal surface of sheep intestines. Plain catgut resorbs quickly in the oral cavity, rarely lasting longer than 3 to 5 days. Gut that has been treated by tanning solutions (chromic acid) and is, therefore, termed “chromic gut,” lasts longer—up to 7 to 10 days. Plain and chromic gut suture are packaged in a moist state to help preserve their suturing properties. If they dry out, they become brittle and will not easily pass through tissue. Thus, when using a gut suture, it is important to not open the inner package until the surgeon is ready to use it. If the suture becomes dry or caked with blood, the suture can be drawn through moistened gauze to restore its working properties. Note that chromic gut suture should not be left soaking in any solution, because this will tend to leach out the chromic salts, speeding its tissue resorption. The composition and monofilament nature of a gut suture gives it an unneeded elastic memory property. Thus, when the suture is drawn from the package, it tends to retain its curled form. Some of this elastic memory can be removed by gently tugging on the suture to help straighten it.

Several synthetic resorbable sutures are also available. These are materials that are long chains of polymers braided into suture material. Examples include polyglycolic acid and polylactic acid. These materials are slowly resorbed, taking up to 4 weeks before they are resorbed. Such long-lasting resorbable sutures are rarely indicated in the oral cavity for basic oral surgery.

Finally, sutures are classified on the basis of being monofilament or polyfilament. Monofilament sutures are sutures such as plain and chromic gut, nylon, and stainless steel. Polyfilament sutures are braided sutures such as silk, polyglycolic acid, and polylactic acid. Sutures made of braided material are easier to handle and tie, are less irritating to a patient’s tongue, and rarely come untied. The cut ends are usually soft and nonirritating to the tongue and surrounding soft tissues. However, because of the multiple filaments, they tend to “wick” oral fluids along the suture to the underlying tissues. This wicking action can carry bacteria along with saliva. Monofilament sutures do not cause this wicking action but can be more difficult to tie and tend to come untied. Also, the cut ends are stiffer, being more irritating to the tongue and soft tissue.

One of the most commonly used sutures for the oral cavity is 3-0 black silk. The size 3-0 has the appropriate amount of strength; the polyfilament (braided) nature of the silk makes it easy to tie and is well tolerated by the patient’s tongue in that the cut ends of the suture tend to lie flat and are not pointed. The color makes the suture easy to see when the patient returns for suture removal. Sutures that are holding mucosa together are usually left in place no longer than 5 to 7 days, so the wicking action is of little clinical importance. Many surgeons prefer 3-0 chromic sutures to avoid the need to later remove them.

Sutures are packaged to help the needle and suture remain sterile before use. They have a nonsterile outer wrapper and sterile inner wrapper. The outer wrapper is designed so that one end can be peeled open, allowing the inner pack to be presented to someone involved in the surgery (Fig II-10) or dropped onto the surgical tray.



print & web 4C/FPO

**FIGURE II-10.** The outer package of the suture peeled open to allow the surgeon or assistant to grasp it in a sterile manner. Reprinted with permission from Hupp<sup>1</sup>.

## Reference

1. Hupp JR, Ellis III E, Tucker MR: Contemporary Oral And Maxillofacial Surgery (ed 6). St. Louis, MO, Elsevier, 2014

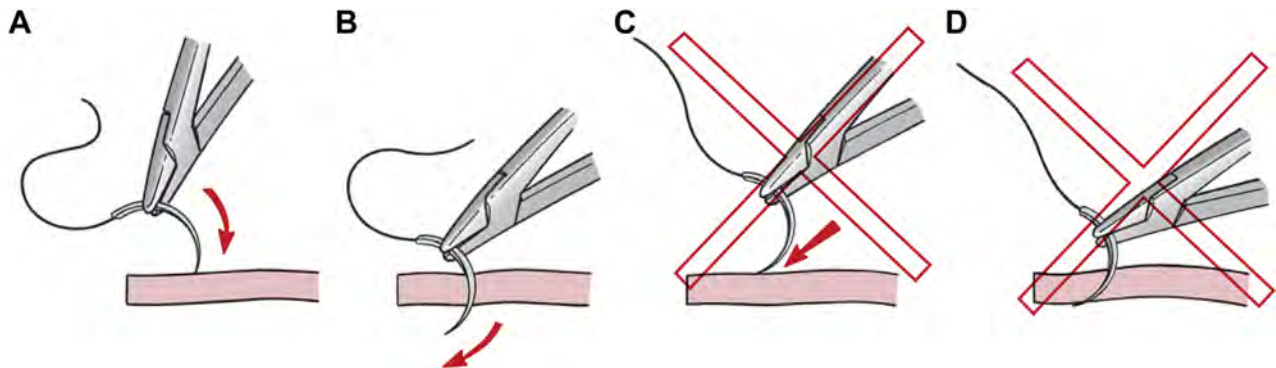
## Section IIC Suturing Techniques

The techniques used for suturing are deceptively difficult. The use of the needle holder and the technique necessary to pass the curved needle through tissue are difficult to master. The following discussion presents the technique used in suturing; practice is necessary before suturing can be performed with skill and finesse. Just as with all such skills, hands-on learning while under the watchful eye of an instructor is critical to becoming able to suture with skill and finesse.

When passing the needle through tissue, the needle should enter the surface of the mucosa close to a right angle, to make the smallest possible hole in the mucosal flap (Fig II-11). If the needle passes through the tissue obliquely, the suture will tear through the surface layers of the flap when the suture knot is tied, which results in greater injury to soft tissue.

When passing the needle through the tissue, the surgeon must ensure that an adequate amount of tissue is taken, to prevent the needle or suture from pulling through the soft tissue. Because the tissue being sutured is a muco-periosteum, it should not be tied too tightly. The minimal amount of tissue between the suture and the edge of the flap should be 3 mm.

In most situations, the suture needle should pass through the tissue following the curvature of the needle with rotation of the wrist or forearm. However, the surgeon must consciously consider how deep to guide the needle so that too much or too little tissue is not engaged. This judgment is learned through experience. In most circumstances in oral surgery, the same amount of tissue should be engaged on each side of the wound being repaired. This means that the distance from the wound edge the needle enters on the first side should equal the distance from the wound edge when the needle emerges on the other side. Similarly, the depth at which the suture needle leaves the subepithelial tissue on the first side should be equal to the depth the needle enters the subepithelial tissue on the other side.

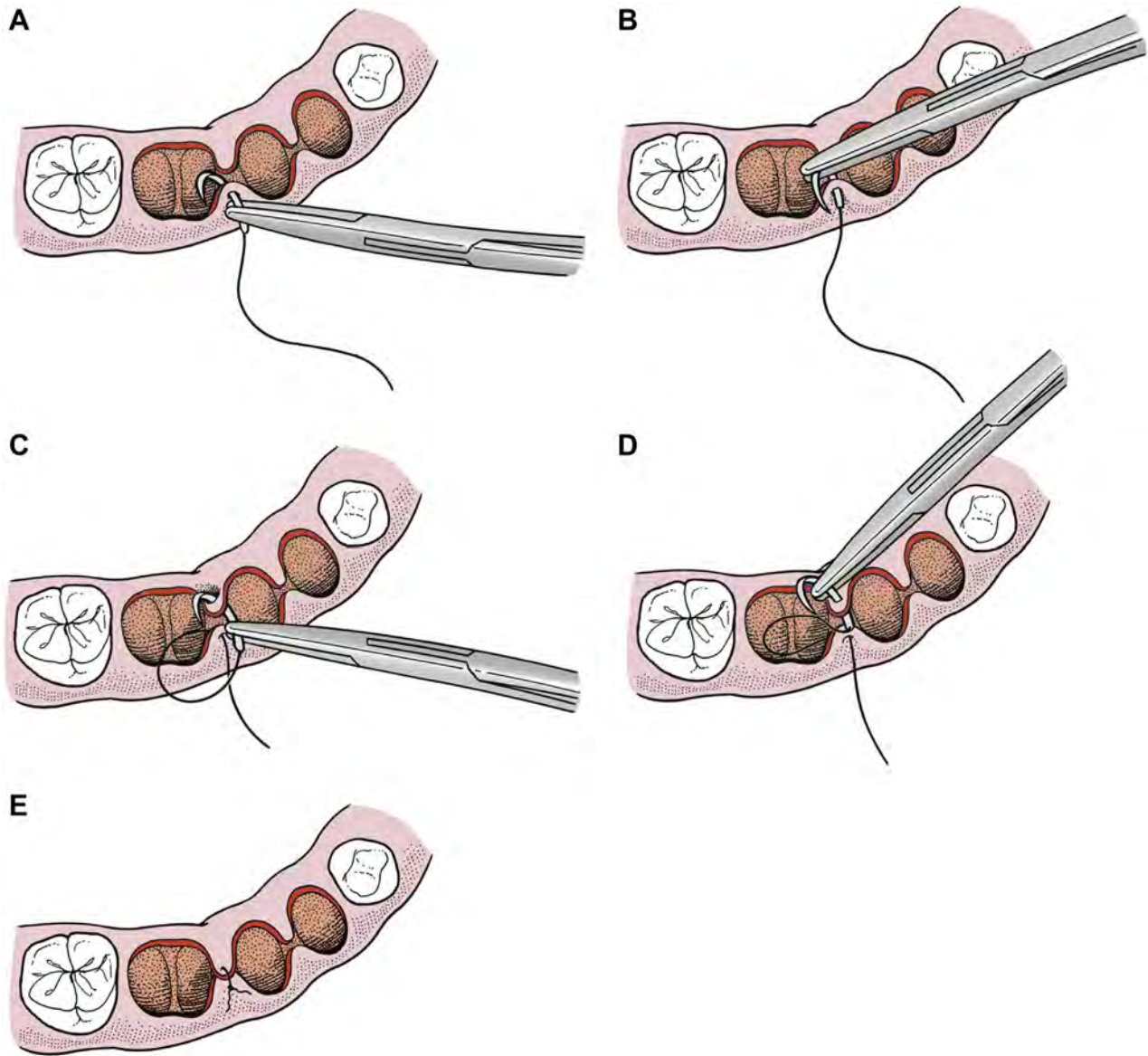


**FIGURE II-11.** A, When passing through the mucosa, the needle should enter the surface of tissue at a 60 to 90° angle. The angle the needle enters is dictated by how deep the suture is intended to run. B, The needle holder should be turned such that the needle passes easily through the tissue. This is accomplished by rotation of the wrist and forearm. C, If the needle enters the soft tissue at too acute an angle and is pushed (rather than turned) through the tissue, tearing of the mucosa with the needle or with the suture is likely to occur and too little tissue will be engaged. D, In most cases, the same amount of tissue should be engaged on both sides of the wound. Reprinted with permission from Hupp<sup>1</sup>.

The most common type of sutures placed in dentistry is the routine interrupted suture. (Some surgeons refer to the routine interrupted suture as a “simple” suture. This is acceptable terminology; however, any type of suturing technique will only become “simple” once it is mastered. Thus, the term “routine” is used in the text.) Routine interrupted sutures are useful to suture divided papillae, to reapproximate the edges of a flap back into place, and to close the soft tissue after a biopsy. The technique for placing and knotting a routine interrupted suture will be presented first, followed by a discussion of other suturing techniques used for dentoalveolar surgery.

The routine interrupted suture is the one most commonly used in the oral cavity. This suture goes through one side of the wound, comes up through the other side of the wound, and is tied in a knot. These sutures can be placed quickly, and the tension on each suture can be adjusted individually. When multiple interrupted sutures are placed, if one suture is lost, the remaining sutures will stay in position, holding the wound closed. When placing multiple adjacent interrupted sutures, they can usually be spaced about 1 to 1.5 cm apart.

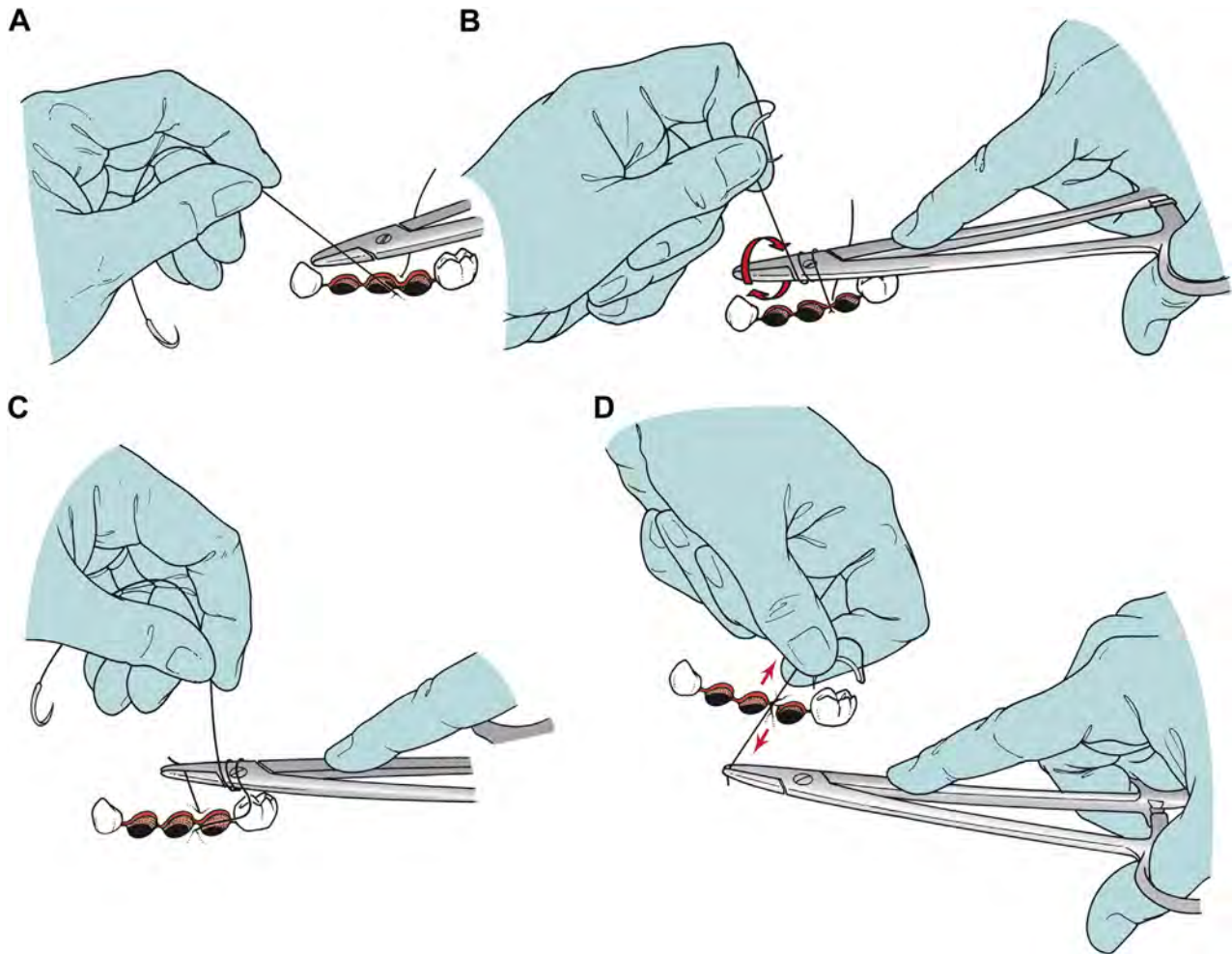
When suturing tissue that has been elevated around the socket of an extracted tooth, such as a papilla that has been cut at the crest of the alveolus, it is usually preferable to suture the facial side of the papilla to the lingual/palatal side. Thus, for example, to suture the papilla between the sockets of teeth 29 and 30, the needle should first enter the epithelial surface of the buccal side of the papilla. Once about one half of the needle is through the papilla, the needle holder should regrasp the needle on the undersurface of the papilla and continue to guide it through the tissue, taking care not to grasp and dull the needle. The surgeon should again regrasp the needle two thirds of the way from the needle and then place the needle through the undersurface of the lingual side of the papilla. Once about one half of the needle is through the papilla, the needle holder should regrasp the needle again to complete guiding it through the lingual side of the cut papilla. Because this is intended to be an interrupted suture, it is ready to be knotted ([Fig II-12](#)).



**FIGURE II-12.** Suturing the papilla between the sockets of teeth 29 and 30 using the routine interrupted suture technique. *A*, The needle should first enter the epithelial surface of the buccal side of the papilla. In most cases, the needle should enter the papilla at a 90° angle. *B*, Once about one half of the needle is through the papilla, the needle holder should regrasp the needle on the undersurface of the papilla and continue to guide it through the tissue, taking care not to grasp and dull the tip of the needle. *C*, The surgeon should again reload the needle two thirds of the way from the tip of the needle and then place the needle through the undersurface of the lingual side of the papilla, trying to reenter at the same depth that the suture exited the facial side of the papilla. *D*, Once about one half of the needle is through the papilla, the needle holder should regrasp the needle again to complete guiding it through the lingual side of the cut papilla. *E*, Because this is intended to be an interrupted suture, it is ready to be knotted.



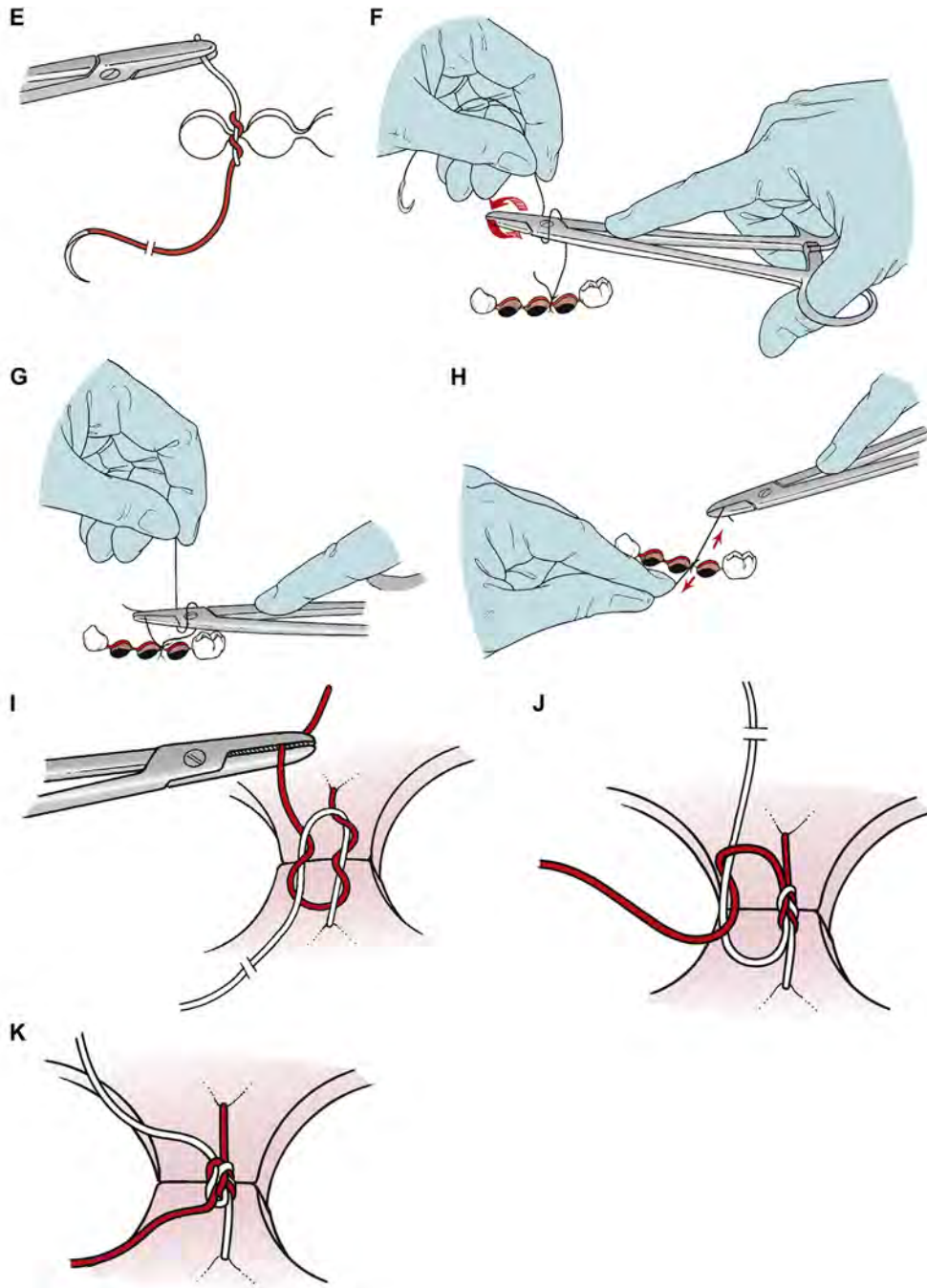
**Figure II-13** illustrates the steps used to tie an interrupted suture using a needle holder (termed an “instrument tie”). It is important to remember that braided sutures, such as black silk sutures, require a single square knot (**Fig II-13A to D**), and monofilament sutures, such as chromic gut, require a second knot to help prevent loosening (**Fig II-13J**). One of the most common mistakes made by inexperienced surgeons performing an instrument tie is to fail to pull enough of the suture through before beginning to make a knot. The short end of the suture, to which the long end connected to the needle will be tied, should be no longer than about 2 cm. It is also important to tighten down the knot by pulling only on the long end of the suture, while keeping the needle holder holding the short end relatively still.



print & web 4C/FPO

**FIGURE II-13.** Most intraoral sutures are tied with an instrument tie. *A*, The suture is pulled through tissue until the short tail of the suture (approximately 1.5–2 cm long) remains. The needle holder is held horizontally by the right hand in preparation for the knot-tying procedure. (Some find it useful to think of the 2 ends of the suture as creating a V. The needle holder is placed in the V, and the long end of the suture is wrapped over the needle holder.) *B*, The left hand then wraps the long end of the suture around the needle holder twice in a clockwise direction to make 2 loops of suture around the needle holder. *C*, The surgeon then opens the needle holder and grasps the short end of the suture very near its end. *D*, The ends of the suture are then pulled in opposite directions (ie, the left hand pulling away and right hand moving a bit toward the surgeon) to tighten the knot. Note that the needle holder should not pull the suture it is holding at all until the knot is nearly tied, rather it should be held in place until the knot is ready to be snugged down; this avoids lengthening that portion of the suture and helps prevent tangling during suturing. (**Fig II-13 continued on next page.**)

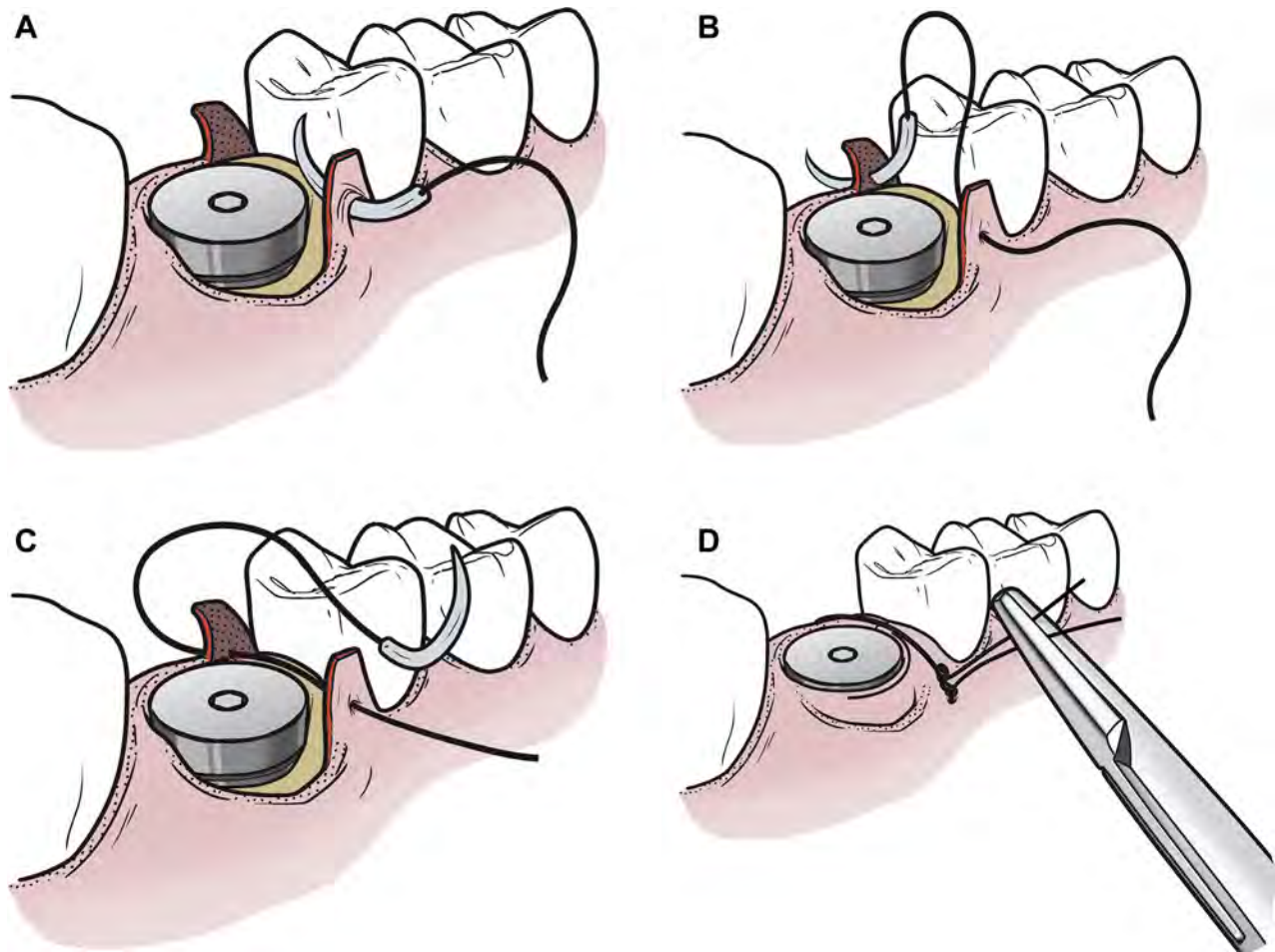




**FIGURE II-13 (cont'd).** *E*, The end of the first step of the surgeon's knot. The double wrap has resulted in a double overhand knot. This increases the friction in the knot and will keep the wound edges together until the second portion of the knot is tied. *F*, The needle holder is now released from the short end of the suture and held in the same position as when the knot-tying procedure began. Take care at this point to not pull on this preliminary knot further or the final knot will be loose. The needle holder is then placed in the V formed by the long end and tail of the suture. The left hand then makes a single wrap in a counterclockwise direction. *G*, The needle holder then grasps the short end (tail) of the suture at its end. *H*, This portion of the knot is completed by pulling this loop firmly down against the previous portion of the knot. *I*, This completes the surgeon's knot. The double loop of the first pass holds the tissue together until the second portion of the square knot can be tied. When using braided suture, such as silk suture, the suture is now ready to be cut. *J*, Most surgeons add a third throw to their instrument tie when using a resorbable and/or monofilament suture material. The needle holder is repositioned in the original position, and 1 wrap is placed around the needle holder in the original clockwise direction. The short end of the suture is grasped and tightened down firmly to form the second square knot. The final throw of 3 knots is tightened firmly. (Note that the first square knot is tightened before creating the second square knot.) Both ends of the suture are now cut, leaving about 1 cm or less of the suture ends with the knot. The final throw of 3 knots is tightened firmly. Modified with permission from Hupp<sup>1</sup>.

**Figure II-14** illustrates a very similar technique of placing an isolated routine suture after an implant procedure. Note that the suture knot is slid to the buccal/labial of the alveolus to move it off the wound surface before being cut. This is also important when using nonresorbable sutures, because this position of the knot will make it less bothersome to the patient and easier to find and cut for removal.

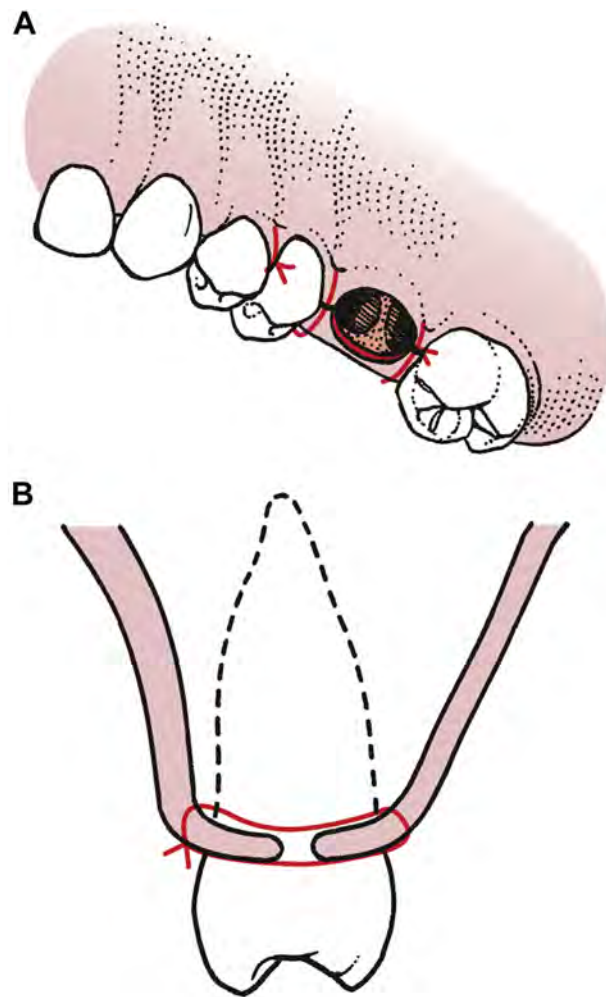
Once the knot securing a suture has been tied, the surgeon or assistant should use a suture scissor to cut the suture. The person cutting the suture should use the tips of the scissors to do the cutting so that they can ensure that nothing beyond the tips of the scissors is being cut. The length of the ends to leave varies, depending on the circumstances. In most situations in which the oral mucosa is being sutured, the ends of the suture should be left no longer than 1 cm.



print & web 4C/FPO

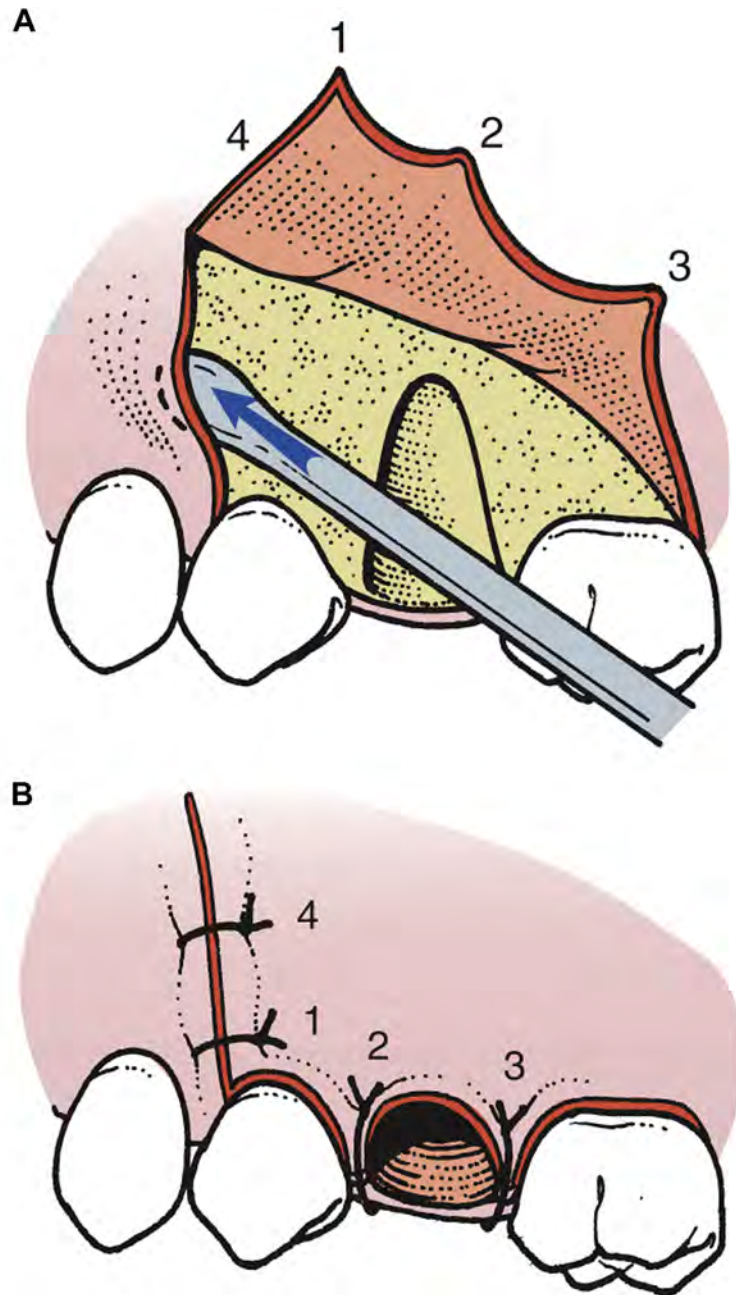
**FIGURE II-14.** An example of placing a single routine suture after an implant procedure. *A*, The needle placed through the facial papilla, taking care to engage enough tissue so the suture is less likely to pull through during knotting. *B*, The second pass of the needle through the undersurface of the lingual papilla, attempting to engage the same amount of tissue as engaged in the facial papilla. If 2 sides of papilla are lying well positioned before suturing, many surgeons will make a single pass with the needle through both sides, rather than using a second pass. *C*, The needle has been brought through the lingual papilla to the facial side to allow for knotting. *D*, Note that the knot has been positioned to the facial side of the wound before it is cut. This keeps it off the wound edge, to keep it from irritating the patient's tongue and, for nonresorbable sutures, in a position making it easier to remove.

When an envelope flap is repositioned into its correct location, it is held in place with sutures that are placed through the papillae only. Sutures are not placed across the empty tooth socket because the edges of the wound would not be supported over sound bone. When reapproximating the flap, the suture is passed first through mobile (usually facial) tissue; the needle is regrasped with the needle holder and passed through the attached tissue of the lingual papilla. If the 2 margins of the wound are close together, the experienced surgeon might be able to insert the needle through both sides of the wound in a single pass. However, for better precision, it is best to use 2 passes in most situations (Fig II-15).



**FIGURE II-15.** A, When an envelope flap is repositioned into its correct location, it is held in place with sutures that are placed through the papillae only. B, Sutures are not placed across the empty tooth socket because the edges of the wound would not be supported over sound bone. Reprinted with permission from Hupp<sup>1</sup>.

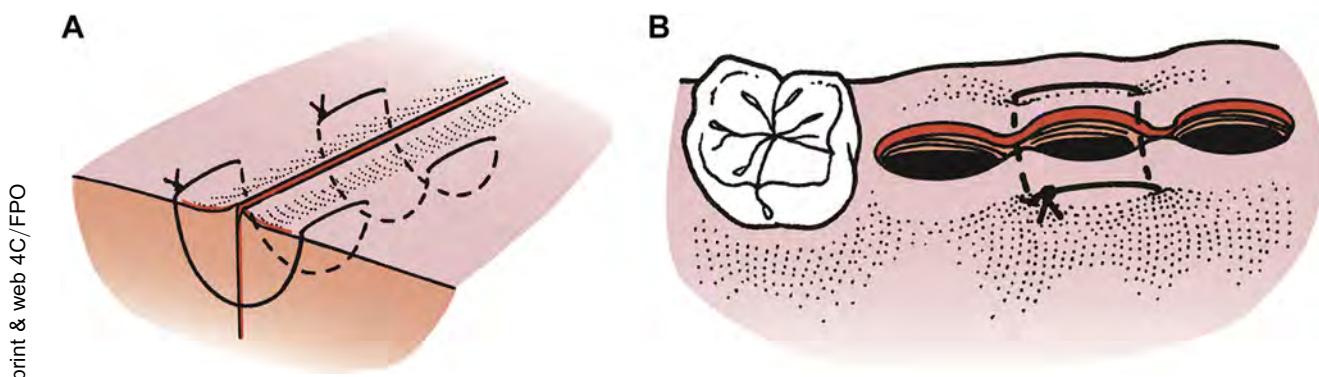
If a three-cornered flap is used, the vertical end of the incision must be closed separately. Two sutures are usually required to close the vertical end properly. Before the sutures are inserted, a periosteal elevator should be used to slightly elevate the non-flap side of the incision, freeing the margin to facilitate passage of the needle through the tissue (Fig II-16). The first suture is placed across the papilla where the vertical release incision was made. This is a known, easily identifiable landmark that is most important when repositioning a three-cornered flap. The remainder of the envelope portion of the incision is then closed, after which the vertical component is closed. The slight reflection of the non-flap side of the incision greatly eases the placing of sutures.



**FIGURE II-16.** A, To make the suturing of the three-cornered flap easier, a periosteal elevator is used to elevate a small amount of fixed tissue so that the suture can be passed through the entire thickness of the mucoperiosteum. B, When the three-cornered flap is repositioned, the first suture is placed at the occlusal end of the vertical-releasing incision (1). The papillae are then sutured sequentially (2, 3). Finally, if necessary, the superior aspect of the releasing incision is sutured (4). Reprinted with permission from Hupp<sup>1</sup>.



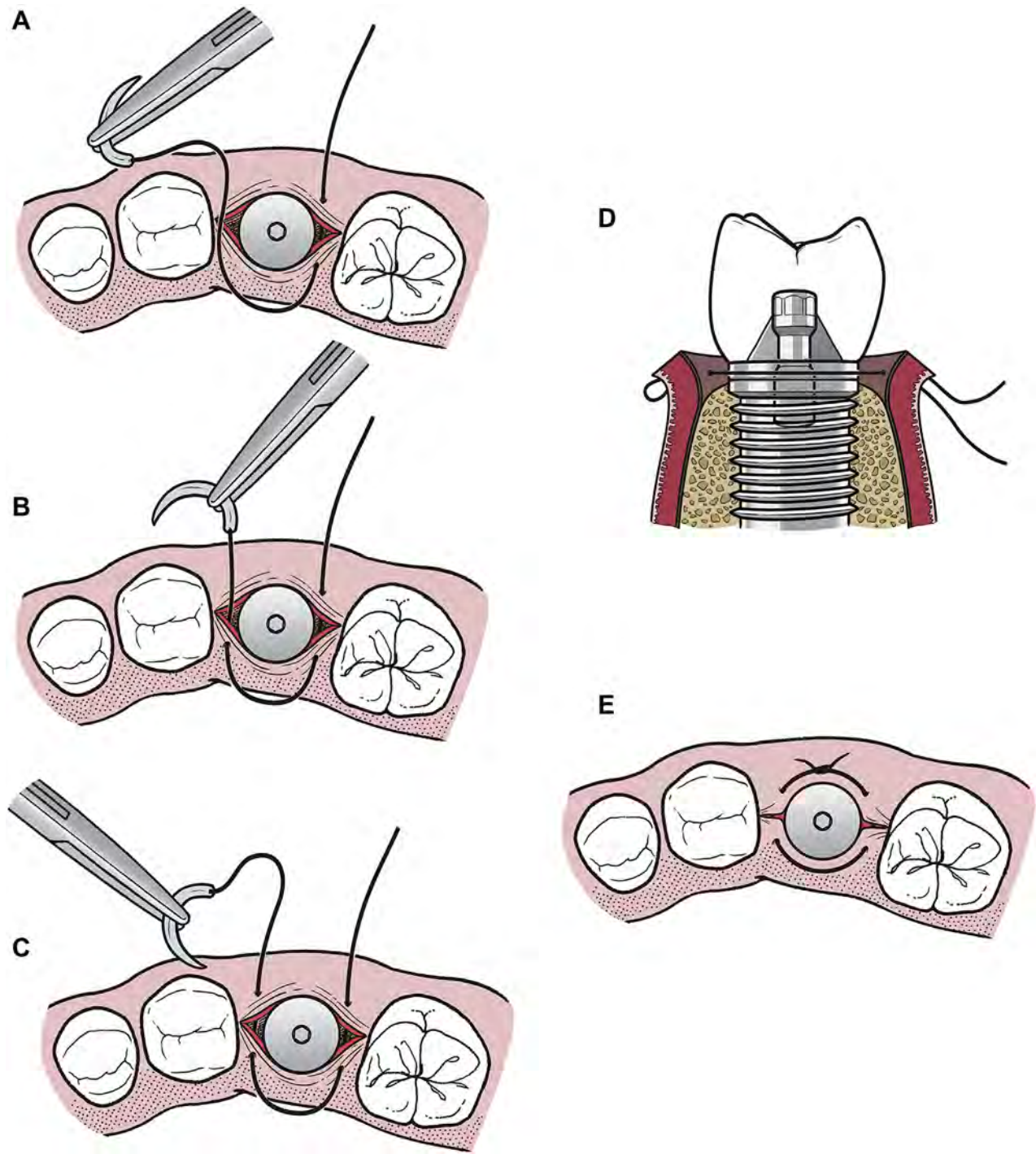
Sutures can be configured in several other different ways. A suture technique that is useful for suturing 2 adjacent papillae with a single suture is the horizontal mattress suture (Fig II-17). This technique is also useful when the edges of the papilla are very fragile, because the suture can enter the tissue further away from the wound edges. When this is done and the suture is properly tightened, the wound edges will usually slightly evert.



print & web 4C/FPO

**FIGURE II-17.** A, A horizontal mattress suture is sometimes used to close soft tissue wounds. The use of this suture decreases the number of individual sutures that must be placed; however, more importantly, it compresses the wound together slightly and everts the wound edges. B, A single horizontal mattress suture can be placed across both papillae of a tooth socket and serves in similarly as 2 individual sutures. Reprinted with permission from Hupp<sup>1</sup>.

When suturing around an implant, the surgeon might prefer to use another variation of the horizontal mattress suture. In the case shown, when the suture is tightened, it will help snug the tissue up to the base of the implant (Fig II-18). A variation of that suture, the figure-of-eight suture, is often used after the extraction of a tooth. This suture holds the 2 papillae in position and puts a cross over the top of the socket (Fig II-1).

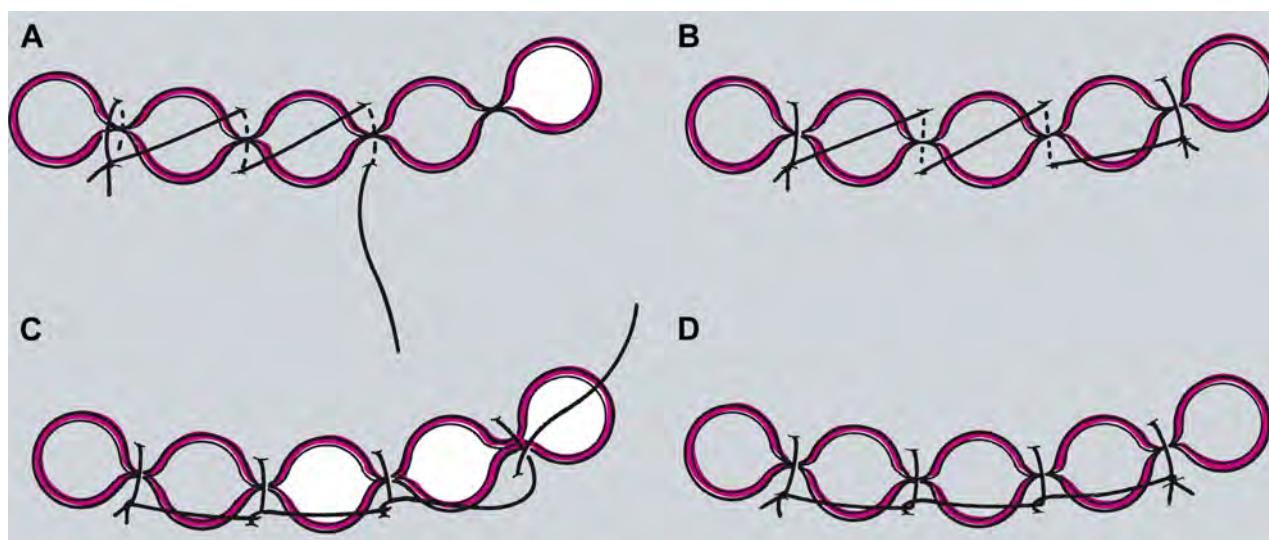


**FIGURE II-18.** Variation on the horizontal mattress suture (note implant crown not shown in occlusal views to allow better visualization of suturing process). *A*, Needle enters tissue on buccal/labial side of tissue distal to implant, and exits on lingual side (single pass shown here). *B* and *C*, Needle next enters lingual tissue on mesial of implant and exits on the buccal/labial aspect (double pass shown here, but can be done as single pass through both sides of the wound). *D*, Cross-sectional view. *E*, Suture tied with instrument tie and cut short.



If a wound is longer than can be readily closed with an interrupted routine or interrupted horizontal mattress suture, a continuous suture technique can be used to efficiently accomplish the closure. When using this technique, a knot does not have to be made for each suture, which makes it quicker to suture a long wound and leaves fewer knots to collect debris. A disadvantage of any continuous suture is that if one suture pulls through the tissue or breaks, the entire suture line can loosen.

The most commonly used continuous suturing technique is the running nonlocking routine suture (often called “baseball” suturing, because the pattern resembles the stitching on a baseball). When placing this type of suture, the distance between the loops of the suture is about 1 to 1.5 cm. While placing a running nonlocking suture, it is useful to maintain gentle tension on the suture loop just placed while making the next tissue pass. This avoids loosening of suture already in the tissue while additional suturing is performed. The tension can be held either by the surgeon’s hand not holding the needle holder or by the assistant (Fig II-19).



print & web 4C/FPO

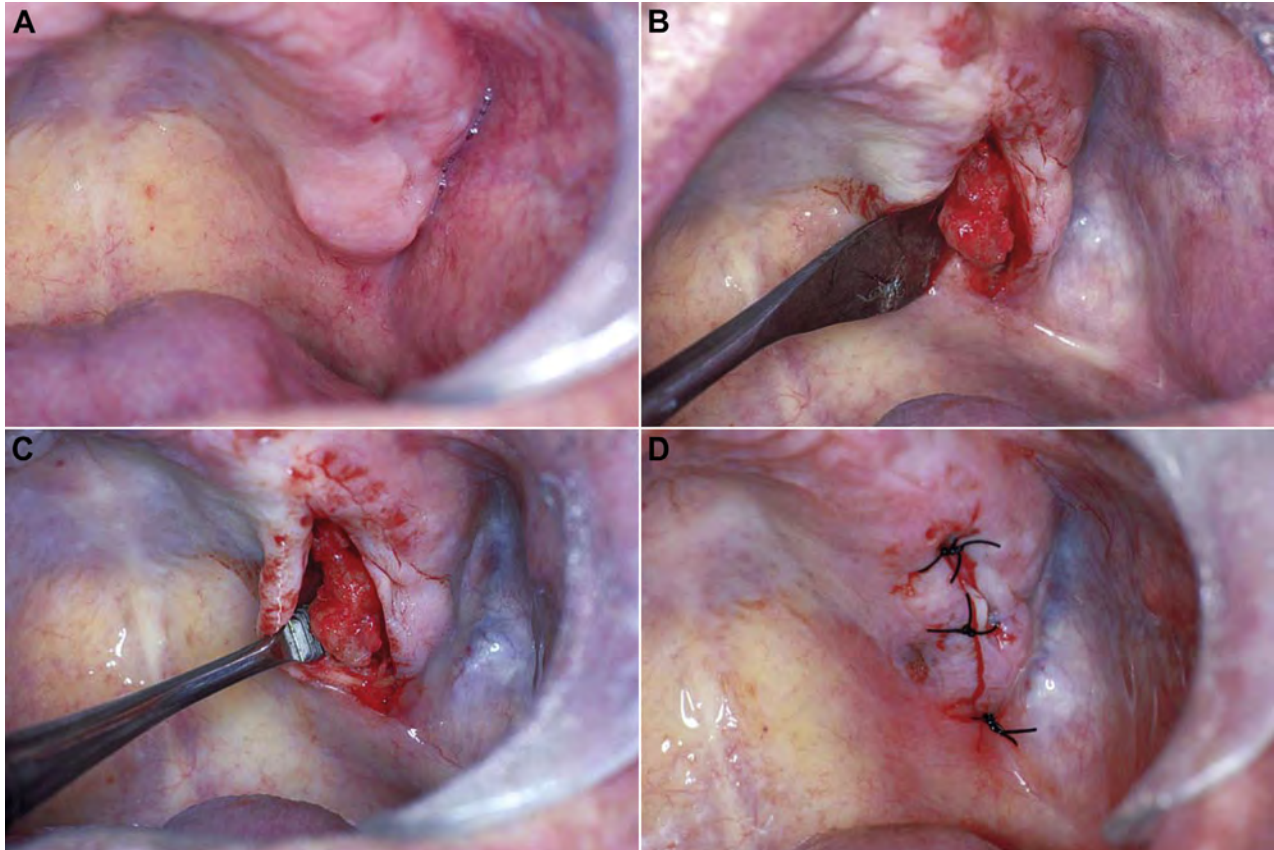
**FIGURE II-19.** When multiple sutures are to be placed after multiple extractions, the incision can be closed with running or continuous sutures. *A*, The first papilla is closed, and the knot tied in the usual way. The long end of the suture is held, and the adjacent papilla is sutured, without the knot being tied, but just with the suture being pulled firmly through the tissue. *B*, The succeeding papillae are then sutured until the final one is sutured and the final knot tied. The knot at the end of continuous suture uses the last placed suture loop as the “short” end to which the long end is tied. *C*, A continuous locking suture can be made by passing the long end of the suture underneath the loop before it is pulled through the tissue. *D*, This puts the suture on the deep periosteal and mucosal surfaces directly across the papilla and can aid in more direct apposition of the tissues. The locking also helps prevent loosening of the suture while additional passes are made. The knot at the end is tied the same way as that used for a nonlocking suture. Reprinted with permission from Hupp<sup>1</sup>.

A continuous routine suture can also be locking. Locking the running suture places points of friction in the suture along the length of the wound being sutured to reduce the tendency of the suture loosening while the remainder of the suture is being placed. Thus, locking of a suture helps keep the earlier placed portions of the continuous suture tight while additional suturing is completed. Locking involves threading the suture through the previous loop of suture. The horizontal mattress suture also can be used in a running fashion and can be either locking or nonlocking.

The most difficult aspect for less experienced surgeons placing continuous sutures relates to knot tying. The initial knot is placed exactly as for an interrupted routine suture; however, once the knot is tightened, the suture attached to the needle is not cut. Rather, it is then used to continue suturing. Once the last suture has been placed, no short end is available to which to tie. Instead, the long end of the suture is tied to the end of the next to the last suture. (This is best learned hands-on with an instructor.)

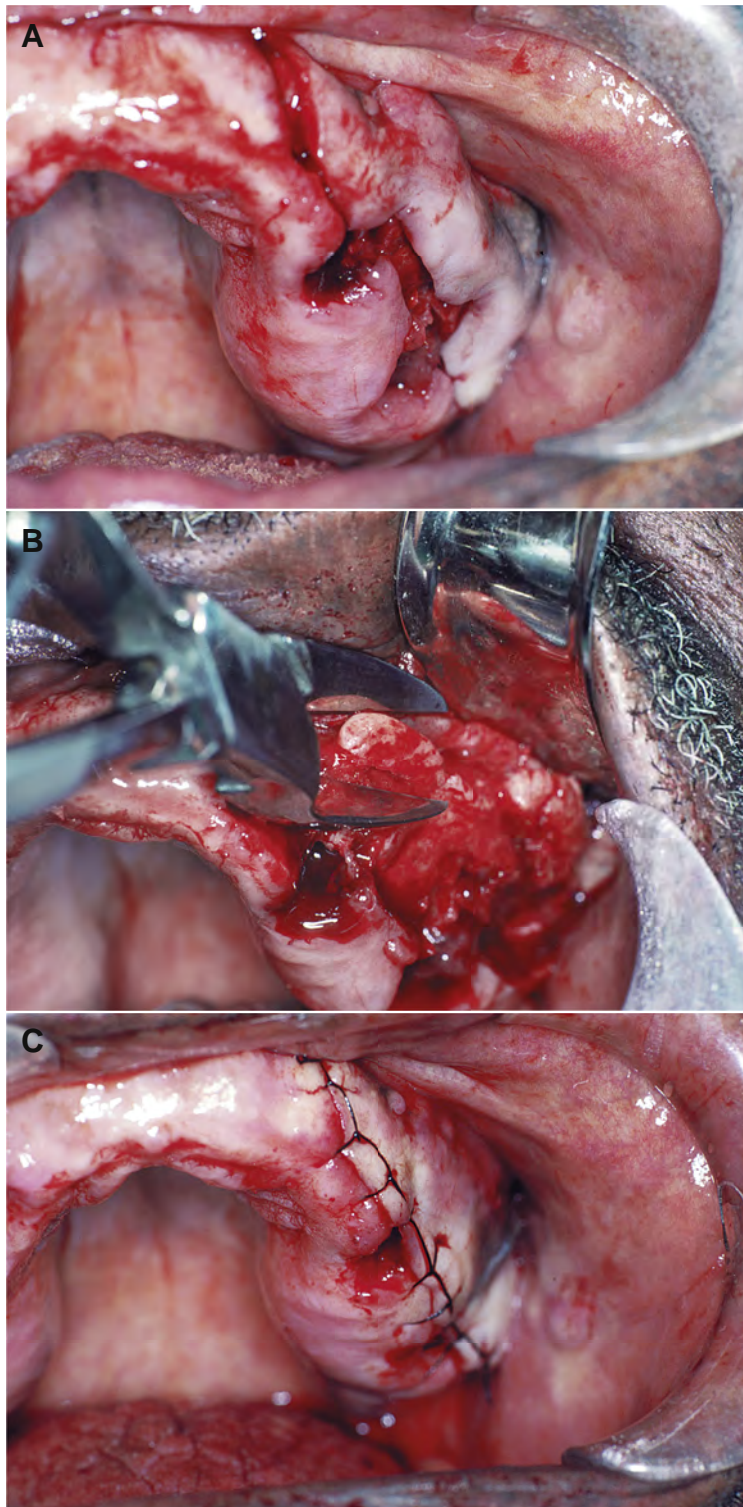
Nonresorbable sutures are left in place for approximately 5 to 7 days. After this time, sutures play no useful role and probably increase the contamination of the underlying submucosa. The suture is cut using the tips of a sharp, pointed pair of suture scissors. Ideally, the cut is made as close as possible to the mucosa to help minimize the amount of contaminated suture drawn through the healing wound. The suture should be removed by being pulled toward the incision line.

Clinical examples of the use of interrupted and continuous sutures are shown in [Figures II-20 and II-21](#).



print & web 4C/FPO

**FIGURE II-20.** An example of the use of interrupted sutures after removal of palatal bony exostosis. *A*, A small palatal exostosis that interferes with proper denture construction in this area. *B*, A crestal incision and mucoperiosteal flap reflection to expose the palatal exostosis. *C*, Use of a bone file to remove bony excess. *D*, Soft tissue closure with interrupted black silk sutures. Reprinted with permission from Hupp<sup>1</sup>.



**FIGURE II-21.** An example of the use of continuous locking sutures after removal of a buccal exostosis. *A*, Gross irregularities of the buccal aspect of the alveolar ridge. After tooth removal, an incision is completed over the crest of the alveolar ridge. (A vertical-releasing incision in the canine area is demonstrated.) *B*, Exposure and removal of buccal exostosis with a rongeur. *C*, Soft tissue closure using continuous locking suture technique with black silk suture. Reprinted with permission from Hupp<sup>1</sup>.

## Reference

1. Hupp JR, Ellis III E, Tucker MR: Contemporary Oral And Maxillofacial Surgery (ed 6). St. Louis, MO, Elsevier, 2014



## Section III Surgical Pathology

### Introduction to Diagnostic Pathology

Dentists often find oral soft tissue abnormalities when examining their patients. Regularly the patient was not aware of any problems in the area in question. Some of these abnormal findings can be diagnosed based on their appearance and history, whereas others require more diagnostic steps. One available option to reach a diagnosis is the performance of a biopsy; namely, taking tissue for examination under a microscope.

This section will help guide the student learning to perform oral soft tissue biopsies. Before discussing how biopsies are performed, Part A reviews the steps that should be taken when deciding whether a biopsy is indicated and, if so, the type of biopsy that should be performed. The question of whether the general dentist should perform a particular biopsy or consider referral to an oral and maxillofacial surgeon also is covered. Part B covers the performance of a biopsy of oral soft tissues.

As with suturing, this section is designed to serve as a student guide to complement faculty instruction on the topic of diagnosing suspicious oral lesions.

### Section III A Diagnostic Strategy

#### HISTORY OF THE SPECIFIC LESION

It is a generally accepted axiom in medicine that many systemic diseases (up to 90%) can be diagnosed by gathering a detailed, annotated medical history. The same can be true of many oral lesions when the diagnostician is familiar with the natural history of the more common diseases. Questioning the patient who has a potentially pathologic condition should include the following:

1. *How long has the lesion been present?* The duration of a lesion can provide valuable insight into its nature. For instance, a lesion that has been present for several years might be congenital and is more likely benign, whereas a rapidly developing lesion is considered more ominous. Although establishing the duration of a lesion provides valuable information, duration must be taken in context with other elements of the history because the lesion might have been present for an extended period before the patient became aware of its presence.
2. *Has the lesion changed in size?* A change in the radiographic or clinical size of a lesion, or both, is an important piece of information that the dentist must determine. An aggressive, enlarging lesion is more likely to be malignant, whereas a slower-growing lesion suggests a possibly benign lesion. By combining information on the growth rate with findings regarding the duration of presence, one can make a more accurate assessment of the nature of the lesion.
3. *Has the lesion changed in character or features (eg, a lump becoming an ulcer or an ulcer starting as a vesicle)?* Noting changes in the physical characteristics of a lesion often can assist in the diagnosis. For example, if an ulcer began as a vesicle, then it could suggest a localized or systemic vesiculobullous or viral disease.

4. *What symptoms are associated with the lesion (eg, pain, altered function, anesthesia or paresthesia, abnormal taste or odors, dysphagia, tenderness of cervical lymph nodes)?* If painful, is the pain acute or chronic, constant or intermittent? What increases or decreases the pain? Lesions with an inflammatory component are most often associated with pain. Cancers, erroneously believed by many to be painful, actually are typically painless unless secondarily infected. Sensory nerve changes, such as numbness or tingling, often occur with a malignant or inflammatory process unless other identifiable causes can be ascertained. Dysphagia can suggest changes in the floor of the mouth or in the parapharyngeal tissues. Swelling often can result from and occur with oral lesions, indicating an expansile process from any number of causes, including inflammation, infection, cysts, or tumor formation. The patient might indicate a sensation of fullness even before the doctor can actually visualize or verify the swelling during clinical examination. Painful lymph nodes usually indicate an inflammatory or infectious cause, but also can be a manifestation of malignancy.
5. *What anatomic locations are involved?* Certain lesions have a predilection for certain anatomic areas or tissues. Noting whether the lesion is confined to keratinized or nonkeratinized tissues, regions with salivary gland tissues, or areas of neural or vascular anatomy sometimes can provide clues to the diagnosis.
6. *Are there any associated systemic symptoms (eg, fever, nausea, malaise)?* Has the patient noted any similar or concurrent changes elsewhere in the body or had similar lesions in the oral or perioral tissues in the past? The dentist should look for possible relations or manifestations from related systemic diseases or conditions. For example, many systemic viral conditions (eg, measles, mumps, mononucleosis, herpes, and acquired immunodeficiency syndrome) can cause oral manifestations concurrent with the systemic involvement. Autoimmune conditions also can manifest with oral lesions. Many oral ulcerative conditions also can present lesions elsewhere in the body (eg, pemphigus, lichen planus, erythema multiforme, sexually transmitted infections). Other factors could include drug abuse or injuries from domestic violence.
7. *Is there any historical event associated with the onset of the lesions (eg, trauma, recent treatment, exposure to toxins or allergens, or visits to foreign countries)?* One of the initial steps the dentist should take when a lesion is noted is to seek a possible explanation based on the patient's medical, dental, family, or social histories. Frequently, oral and perioral lesions can be caused by parafunctional habits, hard or hot foods, application of medications not intended for topical use, recent trauma, conditions involving the dentition (eg, caries, periodontal disease, fractured teeth), or an identified event or exposure.



## CLINICAL EXAMINATION

When a lesion is discovered, careful clinical and, when indicated, radiographic examinations and palpation of regional lymph nodes are mandatory. Once the examination is complete, a detailed description of all objective and subjective findings should be documented in the patient's chart. A drawing or a graphic schematic of the location, orientation, general shape, and dimensions of the lesion in the patient record is helpful. The use of standardized illustrations can simplify the documentation. In addition, good-quality digital photographs are useful for documentation and can aid the pathologist. Details, descriptions, and drawings allow the dentist or subsequent referral specialists to evaluate the course of the lesion over time and determine whether it is enlarging, its features are changing, or if new lesions are appearing in different anatomic areas.

An examination is classically described as a process that includes inspection, palpation, percussion, and auscultation. In the head and neck region, inspection and palpation are more commonly used as diagnostic modalities, with inspection always preceding palpation. Early inspection facilitates creating a description of the lesion before it is handled because some lesions are so fragile that manipulation of any kind might result in hemorrhage or rupture of a fluid-filled lesion or loss of loosely attached surface tissues, which would compromise any subsequent examinations. Percussion is reserved for examination of the dentition. Auscultation is used infrequently but is important when examining for suspected vascular lesions.

The following list includes some important additional points to be considered during the inspection of a lesion:

1. *Anatomic location.* Pathologic lesions can arise from any tissue within the oral cavity, including the epithelium, subcutaneous and submucosal connective tissues, muscle, tendon, nerve, bone, blood vessels, lymphatic vessels, or salivary glands. The dentist should attempt to ascertain, as much as possible, which tissues are contributing to the lesion, based on the anatomic location of the lesion. For example, if a mass appears on the dorsum of the tongue, then the dentist would logically consider an epithelial, connective tissue, lymphatic, vascular, glandular, neural, or muscular origin. Similarly, a mass on the inner aspect of the lower lip would prompt the dentist to include a minor salivary gland origin in the differential diagnosis, in addition to a connective tissue origin and other possibilities. Certain lesions can have unique anatomic characteristics, such as the linear tendencies of herpes zoster lesions as they follow neural pathways. The role of trauma should always be entertained as a possible source of the lesion (ill-fitting dental appliances, parafunctional habits such as cheek biting, sharp edges on teeth or restorations, trauma from acts of domestic or other types of violence). Pulpal, periapical, and periodontal pathologic or inflammatory conditions also cause a large percentage of oral lesions.
2. *Overall physical characteristics.* Appropriate medical terminology should always be used to describe clinical findings in the record because lay terminology can be misleading and nonspecific. Terms such as *ulcer* or *nodule* might be interpreted differently by different examiners. [Figure III-1](#) lists several common physical descriptions that are useful in describing oral and maxillofacial pathologic entities. Terms such as those listed in [Figure III-1](#) should generally be used to describe the characteristics of a lesion. Lay terms such as *swelling* and *sore* are generally not helpful and could be subject to misinterpretation.

- *Bulla (pl. bullae)*: a blister; an elevated, circumscribed, fluid-containing lesion of skin or mucosa
- *Crusts (crusted)*: dried or clotted serum on the surface of the skin or mucosa
- *Dysplasia (dysplastic)*: any abnormal development of cellular size, shape, or organization in tissue
- *Erosion*: a shallow, superficial ulceration
- *Hyperkeratosis*: an overgrowth of the cornified layer of epithelium
- *Hyperplasia (hyperplastic)*: an increased number of normal cells
- *Hypertrophy (hypertrophic)*: an increase in size caused by an increase in the size of cells, not in the number of cells
- *Keratosis (keratotic)*: An overgrowth and thickening of cornified (horned layer) epithelium
- *Leukoplakia*: a slowly developing change in mucosa characterized by firmly attached, thickened, white patches
- *Macule*: a circumscribed, nonelevated area of color change that is distinct from adjacent tissues
- *Malignant*: anaplastic; a cancer that is potentially invasive and metastatic
- *Nodule*: a large, elevated, circumscribed, solid, palpable mass of the skin or mucosa
- *Papule*: a small, elevated, circumscribed, solid, palpable mass of the skin or mucosa
- *Plaque*: any flat, slightly elevated, superficial lesion
- *Pustule*: a small, cloudy, elevated, circumscribed, pus-containing vesicle on the skin or mucosa
- *Scale*: a thin, compressed, superficial flake of cornified (keratinized) epithelium
- *Stomatitis*: any generalized inflammatory condition of the oral mucosa
- *Ulcer*: a crater-like, circumscribed surface lesion resulting from necrosis of the epithelium
- *Vesicle*: a small blister; a small, circumscribed elevation of skin or mucosa containing serous fluid

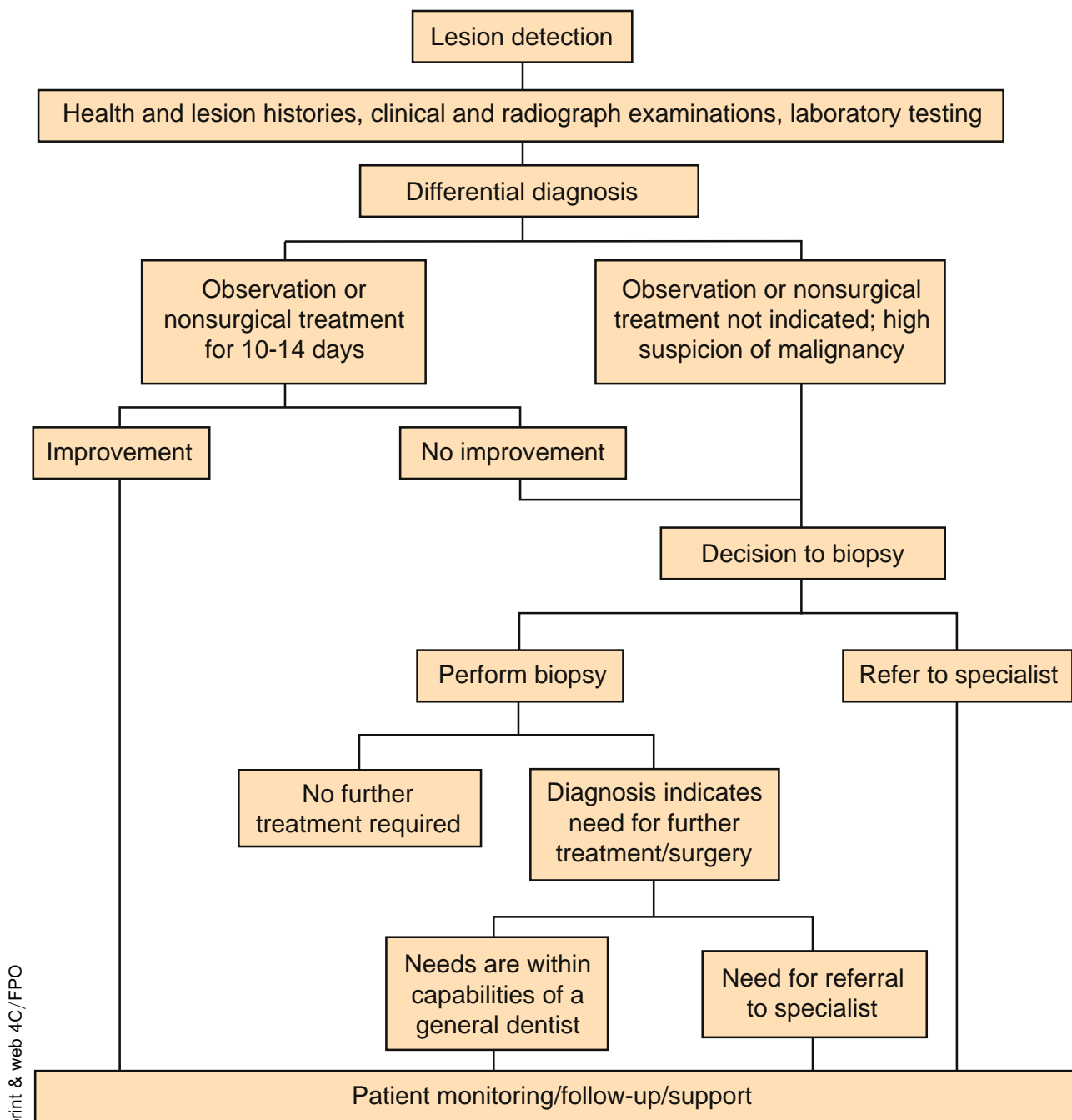
**FIGURE III-1.** Descriptive pathology terminology. Reprinted with permission from Hupp<sup>1</sup>.

3. *Single versus multiple.* The presence of multiple lesions is an important feature. When multiple ulcerations are found within the mouth, the dentist should think of specific possibilities for the differential diagnosis. To find multiple or bilateral neoplasms in the mouth is unusual, whereas vesiculobullous, bacterial, and viral diseases commonly present such a pattern. Similarly, an infectious process can exhibit outward spread because 1 lesion infects the adjacent tissues with which it has had contact.
4. *Size, shape, and growth.* Documentation of the size and shape of the lesion should be made, as noted earlier. A small metric ruler made of a material that can be disinfected (eg, metal or plastic) is useful to have on hand. The ruler is valuable for measuring the diameter of a clinically evident lesion; then, those measurements can be entered into the record with the drawing. The shape of the lesion also should be noted: whether the lesion is flat or slightly elevated, endophytic (growing inward) or exophytic (growing outward from the epithelial surface), and sessile (broad based) or pedunculated (on a stalk).
5. *Surface appearance.* The epithelial surface of a lesion can be smooth, lobulated (verruciform), or irregular. If ulceration is present, then the characteristics of the ulcer base and margins should be recorded. Margins of an ulcer can be flat, rolled, raised, or everted. The base of the ulcer can be smooth, granulated, or covered with fibrin membrane, slough, or hemorrhagic crust (scab) or can have the fungating appearance that is characteristic of some malignancies.
6. *Color.* The surface color(s) of a lesion can reflect various characteristics and even the origin of many lesions. A dark bluish swelling that blanches on pressure suggests a vascular lesion, whereas a lighter-colored, bluish lesion that does not blanch might suggest a mucus-retention cyst. A pigmented lesion within the mucosa can suggest a "traumatic tattoo" of restorative material or a more ominous melanotic tumor. Keratinized white lesions can reflect a reaction to repetitive local tissue trauma or represent potentially premalignant changes. An erythematous (or mixed red-and-white) lesion can represent an even more ominous prognosis for dysplastic changes than a white lesion. Inflammation can be superimposed on areas of mechanical trauma or ulceration, resulting in a varied color from one examination to the next.
7. *Sharpness of borders and mobility.* If a mass is present, then the dentist should determine whether it is fixed to the surrounding deep tissues or freely movable. Determining the boundaries of the surface lesion will aid in establishing whether the mass is fixed to adjacent bone, arising from bone and extending into adjacent soft tissues, or only infiltrating the soft tissue.
8. *Consistency when palpated.* Consistency can be described as soft or compressible (eg, a lipoma or abscess), firm or indurated (eg, a fibroma or neoplasm), or hard (eg, torus or exostosis). *Fluctuant* is a term used to describe the wavelike motion sensed during bi-digital palpation of a lesion with nonrigid walls and that contains fluid. This valuable sign can be elicited by palpating with at least 2 fingers in a rhythmic fashion. As 1 finger exerts pressure, the opposing finger perceives the impulse transmitted through the fluid-filled cavity.
9. *Presence of pulsation.* Palpation of a mass can disclose a rhythmic pulsation that is suggestive of a major vascular component. This sensation can be subtle and is especially important when dealing with intrabony lesions. The pulsation can be accompanied by a palpable vibration, called a *thrill*. If a thrill is palpated, auscultation of the area with a stethoscope might disclose a *bruit*, or audible murmur, in the area. Invasive procedures on lesions with thrills, bruits, or both should be avoided, and patients should be referred to specialists for treatment because life-endangering hemorrhage can result if surgical intervention (biopsy) is attempted.
10. *Examination of regional lymph nodes.* No evaluation of an oral lesion is complete without a thorough examination of the regional lymph nodes. This examination should be accomplished before any biopsy procedure. Sometimes, lymphadenitis develops in the regional nodes after a surgical procedure such as biopsy, thus creating a subsequent diagnostic dilemma. Then, it can become difficult to differentiate reactive lymphadenitis as a surgical sequela from coincidental regional infection or inflammation from metastatic spread of the tumor in question.

## PREBIOPSY MONITORING

Any undiagnosed or suspicious change in oral tissues that cannot be explained by localized trauma (and the trauma source corrected) or other factors should be followed up in 7 to 14 days. If the lesion enlarges or expands, develops an altered appearance, or does not respond as expected to local therapy, a biopsy is usually indicated. See the flow chart presented in [Figure III-2](#). Areas of *leukoplakia* (which is used as a clinical term, not a pathology term) can be problematic because up to 20% of those areas (and 100% of erythroplakia lesions) exhibit histologic evidence of dysplasia or frank malignancy. High-risk areas of the mouth include the floor of the mouth, the lateral and ventral surfaces of the tongue, and the buccal and lower lip mucosa. Areas of redness or pebbling within areas of leukoplakia are especially troubling. Incisional biopsy specimens from at least 1 suspicious area are generally indicated ([Figs III-3, III-4](#)).

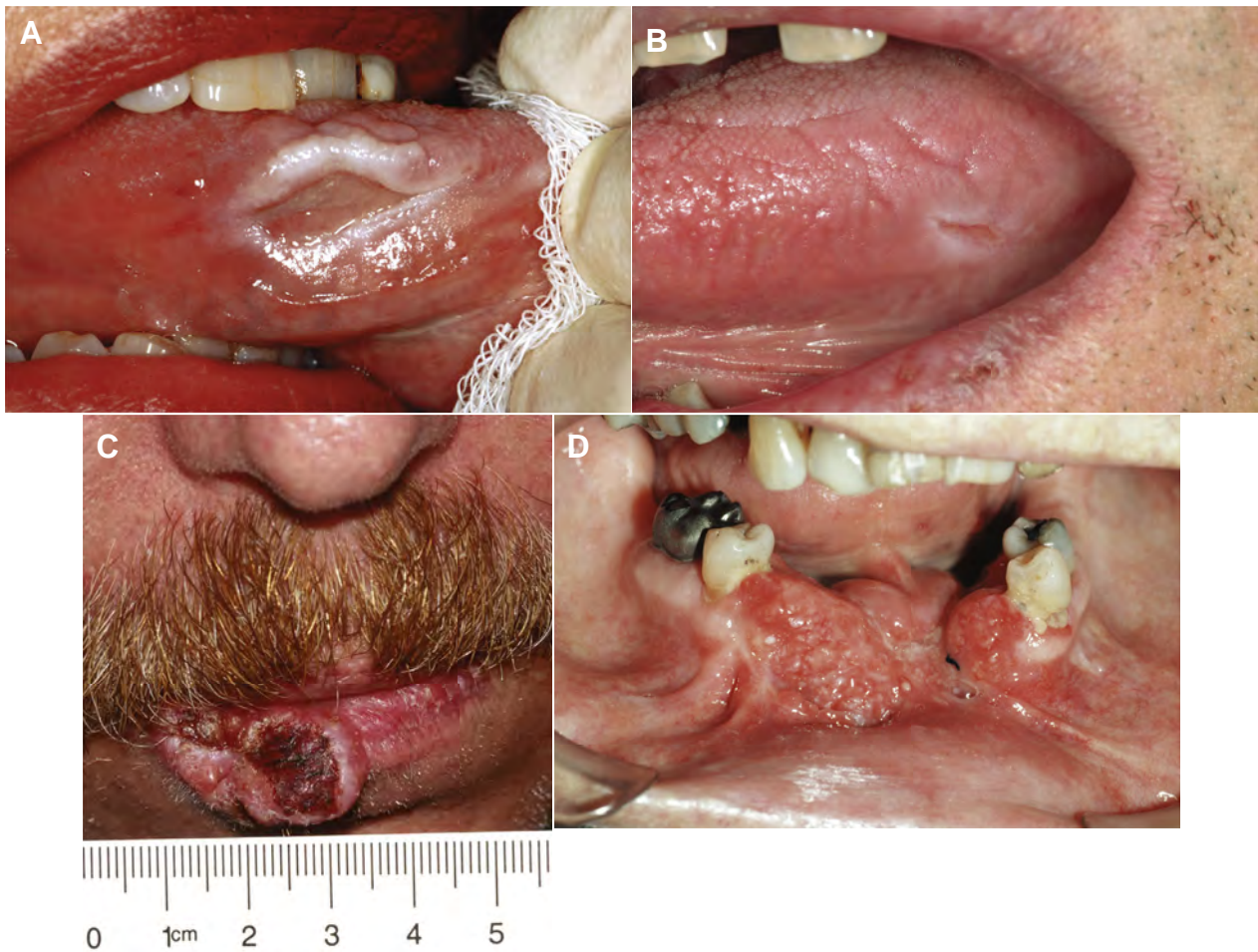During subsequent examinations, the patient record should provide details on whether the observed lesion has improved or not improved and the dentist's plan for subsequent management (ie, continued observation on a structured timetable, continued local treatment, biopsy, or referral).



**FIGURE III-2.** Decision tree diagram for managing suspicious lesions. Reprinted with permission from Hupp<sup>1</sup>.

- *Bleeding*: lesion bleeds on gentle manipulation
- *Duration*: lesion has persisted for more than 2 weeks
- *Erythroplasia*: lesion is totally red or has a speckled red and white appearance
- *Fixation*: lesion feels attached to adjacent structures
- *Growth rate*: lesion exhibits rapid growth
- *Induration*: lesion and surrounding tissue are firm to the touch
- *Ulceration*: lesion is ulcerated or presents as an ulcer

**FIGURE III-3.** Characteristics of lesions that raise suspicion of malignancy. Reprinted with permission from Hupp<sup>1</sup>.



print & web 4C/FPO

**FIGURE III-4.** Examples of lesions that should be considered for biopsy. *A*, Ulcer on the lateral border of the tongue. In this case, it was a traumatic ulcer from biting. *B*, Another ulcer on the lateral border of the tongue. In this case, it was from a sharp edge of a fractured tooth cusp. *C*, Large ulcer of the lower lip, especially if in a patient with a history of smoking. This lesion was squamous cell carcinoma. *D*, Typical appearance of squamous cell carcinoma of the alveolar ridge. Reprinted with permission from Hupp<sup>1</sup>.



### BASIC TENETS OF FOLLOW-UP AND REFERRAL

Failure to diagnose and refer a patient with a possible pathologic condition in a timely manner has become one of the leading causes of litigation in the medical profession. The dentist should not delegate examination of patients for pathologic conditions to auxiliary staff such as dental hygienists. Although most hygienists are well-trained to be observant of soft tissue changes in the oral cavity, the ultimate responsibility for the detection of pathologic conditions (including oral cancer screening) rests with the dentist. Delegation of this duty is not permitted by law. If the dentist does not follow-up on the hygienist's discovery of abnormal tissues, then the patient record should reflect the rationale for that decision.

If the dentist decides to refer the patient for a second opinion or specialty management, then the referral appointment ideally should be arranged before the patient leaves the office. If left to make the appointment themselves, many patients might fail to do so because of fear, denial, or procrastination. The arranged appointment should be followed with a letter or electronic message from the referring general dentist to the specialist, outlining the details of the case, the concerns, and the requested procedures. A copy of this correspondence should be placed in the patient record. Copies of the specialist's findings, recommendations, procedures, and biopsy findings also should be placed in the patient record. These formal exchanges provide precise documentation that prevents miscommunications between offices and can provide some protection if litigation is initiated later. Returned reports from the pathologist should be acted on promptly. The patient should be notified of the results, and if the results are unexpected or positive requiring further treatment, then the patient should be counseled in person by the dentist.

### BIOPSY OR REFERRAL

Clinicians vary in their surgical interests, training, and skills. Some dentists might be comfortable performing biopsy procedures on their patients, whereas others might refer their patients to a specialist. This is a personal choice and should take several points into consideration.

1. *Health of the patient.* The patient pool in the United States is becoming older, with a growing number of older patients seeking treatment in dental offices. Many of these patients have a history of systemic diseases, multiple medications, or physical compromises that pose an increased surgical risk or potential hazards. However, the presence of such conditions should not considerably delay biopsy examination or referral in most cases. Patients can be referred to an oral-maxillofacial surgeon who is trained to manage patients with special medical needs so that the procedure is carried out as safely as possible.
2. *Surgical difficulty.* If any of the basic surgical principles, such as access, lighting, anesthesia, tissue stabilization, and instrumentation, pose a problem if the dentist were to treat the patient, then referral should be considered. Similarly, as the size of a lesion increases or its position encroaches on important anatomic structures, the potential for serious complications (eg, bleeding and nerve damage) increases. Each dentist should use his or her best judgment when deciding whether the biopsy is within the dentist's surgical abilities or if the patient would be better managed by a more experienced specialist.
3. *Malignant potential.* The dentist who suspects that a lesion is malignant has 2 choices: 1) perform a surgical biopsy after completion of comprehensive diagnostic workup or 2) refer the patient before biopsy is performed to a specialist who can provide definitive treatment if the lesion is shown to be malignant. The latter choice usually represents better service to the patient if the referral can be executed in a prompt and timely manner. In such cases, it is better for the referral specialist to evaluate the lesion before any surgical intervention has compromised its clinical features. Biopsy also can produce reactive lymph nodes that might be unrelated to the original lesion and even spread malignant tissue. Allowing the referral specialist to evaluate the patient before biopsy helps toward a more accurate diagnosis and aids in the formulation of a suitable treatment plan.

## Section III B Soft Tissue Biopsy

### GENERAL PRINCIPLES OF BIOPSY

The term *biopsy* indicates removal of tissue from a living body for microscopic diagnostic examination. Biopsy is the most precise and accurate of all diagnostic tissue procedures and should be performed whenever a definitive diagnosis cannot be obtained using less invasive procedures. The primary purpose of biopsy is to determine the diagnosis precisely so that proper treatment can be provided. It can be useful for distinguishing different lesions that have similar clinical or radiographic appearances.

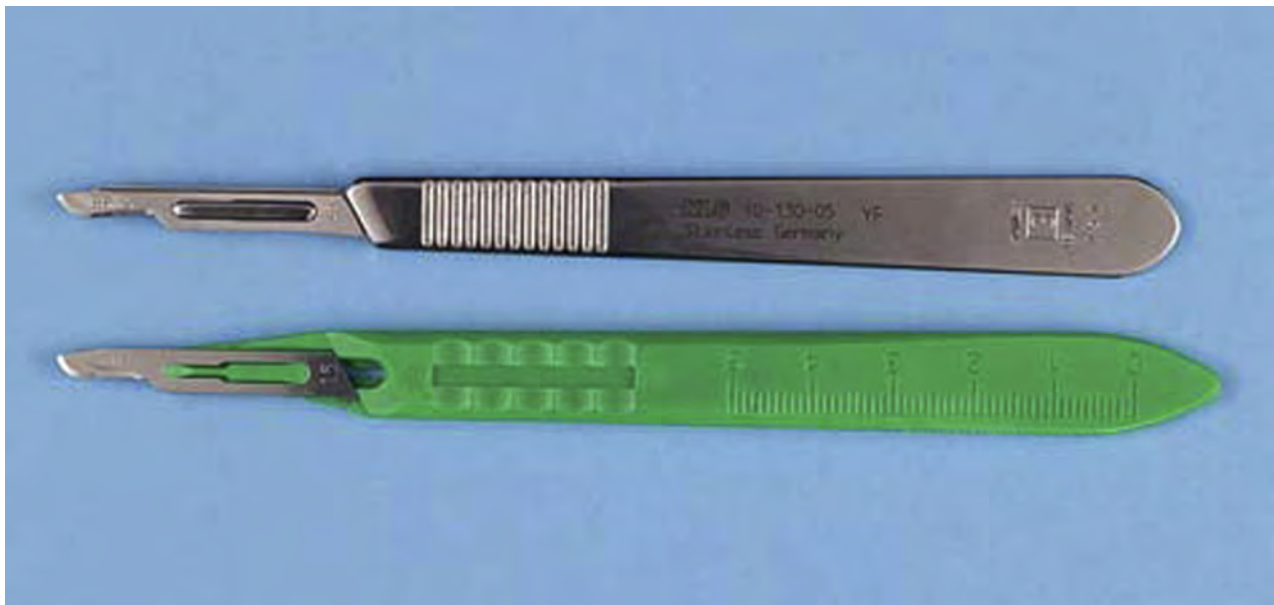Be aware that the term *biopsy* leads many patients to a perception that the dentist suspects malignancy, so discussions that include that word need to be carefully phrased so it will not cause the patient undue alarm or anxiety. In fact, most biopsies of oral tissue help rule out malignancy because most oral lesions are not malignant.

### INSTRUMENTATION

#### *Incising Tissue*

Performing a biopsy of oral soft tissue usually involves incising the tissue with a scalpel. The scalpel is composed of a reusable handle and a disposable, sterile, sharp blade. Scalpels also are available as a single-use scalpel with a plastic handle and fixed blade. The most commonly used handle for oral surgery is the number 3 handle (Fig III-5).

The tip of a scalpel handle is prepared to receive a variety of differently shaped scalpel blades to be inserted onto the slotted portion of the handle. The most commonly used scalpel blade for intraoral surgery is the number 15 blade (Fig III-6).

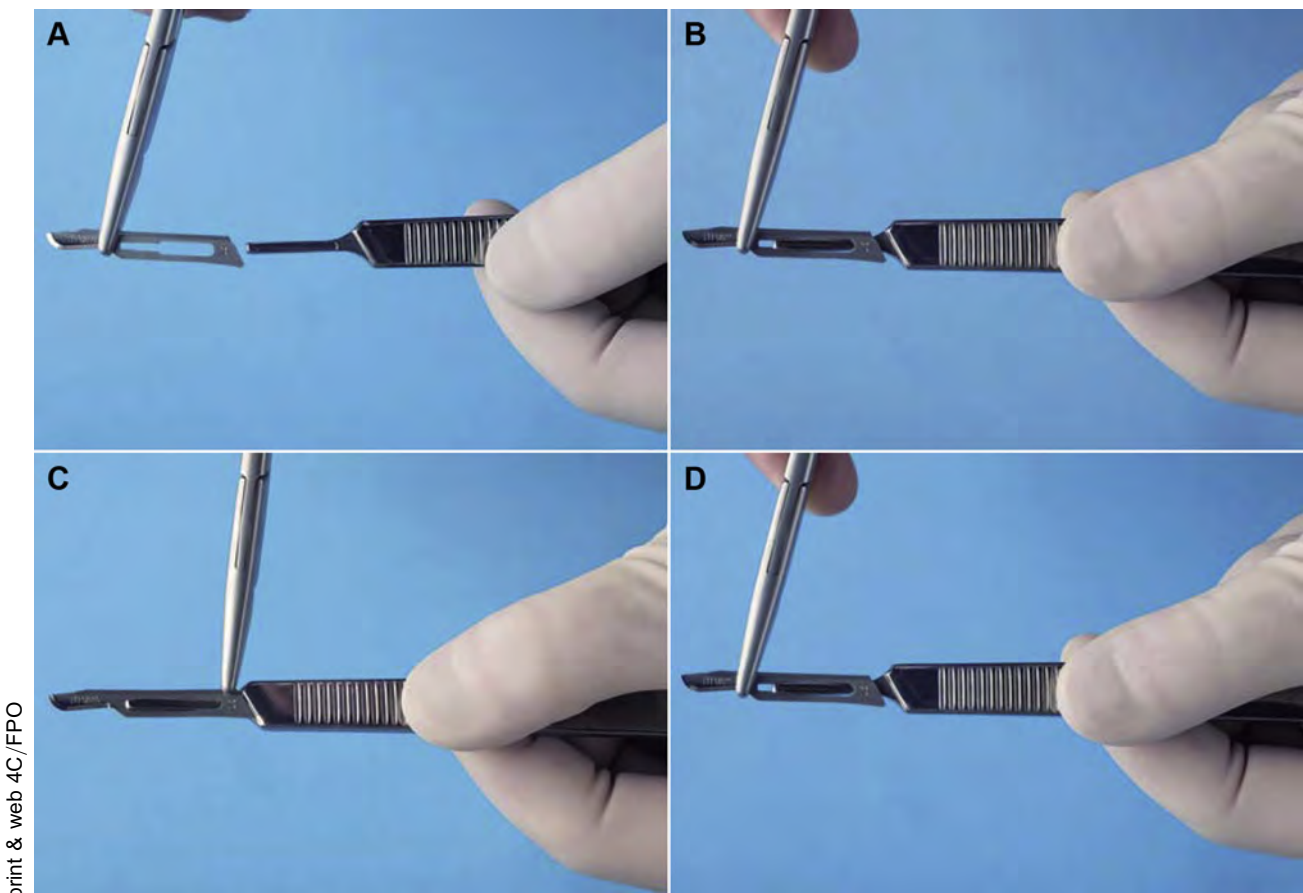


**FIGURE III-5.** Scalpels come in two forms. One has a reusable handle and one-time use disposable blade (*top*) and the other has a blade/handle combination in which the entire blade/handle unit is discarded after one-time use (*bottom*). In both cases the blade or blade/handle unit must be placed into a red sharps disposable box. Reprinted with permission from Hupp<sup>1</sup>.



**FIGURE III-6.** Scalpel blades come in various shapes and sizes. The most common blade used for oral surgery is the #15 blade, the right-most in this figure. Reprinted with permission from Hupp<sup>1</sup>.

The scalpel blade is carefully loaded onto the handle while holding the blade with a needle holder. This lessens the chance of injuring the fingers. The blade is held along the unsharpened edge, where it is reinforced with a small rib, and the handle is held so that the male portion of the fitting is pointing upward (Fig III-7A). Then, the scalpel blade is slid slowly onto the handle along the grooves in the male portion until it clicks



**FIGURE III-7.** A, When loading scalpel blade, the surgeon holds the blade in the needle holder and handle, with the male portion of the fitting pointing upward. B, The surgeon slides the blade onto the handle until it clicks into place. C, To remove the blade, the surgeon uses the needle holder to grasp the end of the blade next to the handle and lifts it to disengage it from the fitting. D, The surgeon gently slides the blade off the handle to dispose in a rigid-sided red sharps container. Reprinted with permission from Hupp<sup>1</sup>.

into position (Fig III-7B). The scalpel is unloaded similarly. The needle holder grasps the end away from the blade (Fig III-7C) and lifts it to disengage it from the male fitting. Then, the scalpel is slid off the handle, always away from the body (Fig III-7D). The used blade is immediately discarded into a specifically designed, rigid-sided sharps container (Fig III-8).

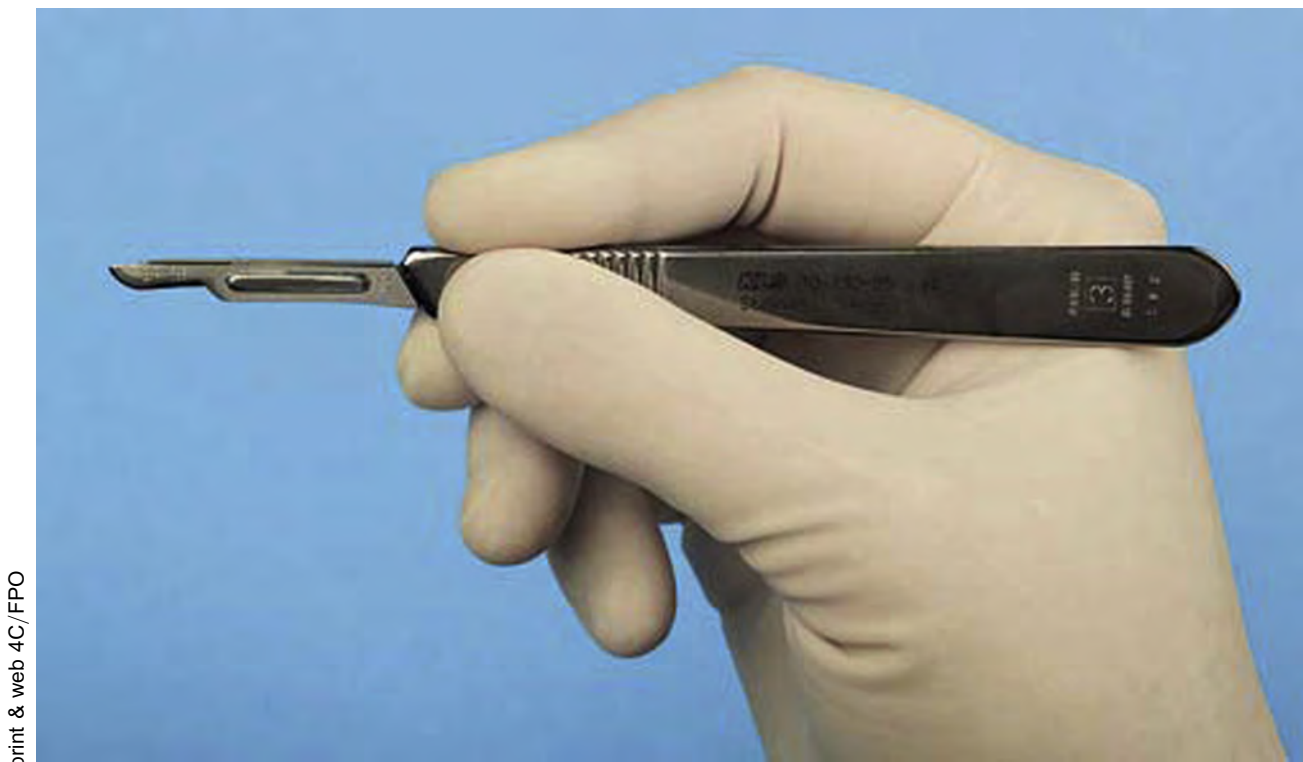

print & web 4C/FPO

**FIGURE III-8.** Rigid-sided red sharps container used to dispose of sharp materials such as scalpel blades, local anesthesia needles, and suture needles.

When using the scalpel to make an incision, the surgeon typically holds it in the pen grasp (Fig III-9) to allow maximal control of the blade as the incision is made. Mobile tissue should be held firmly in place under some tension so that as the incision is made, the blade will incise and not just push away the mucosa. When incising depressible soft tissue, an instrument such as a retractor or a tissue forceps should be used to hold the tissue taut while incising.

Scalpel blades and blade-and-handle sets are designed for single-patient use. Blades dull easily after repeated strokes through keratinized tissue. Dull blades do not make clean, sharp incisions in soft tissue and therefore should be replaced before they become overly dull.



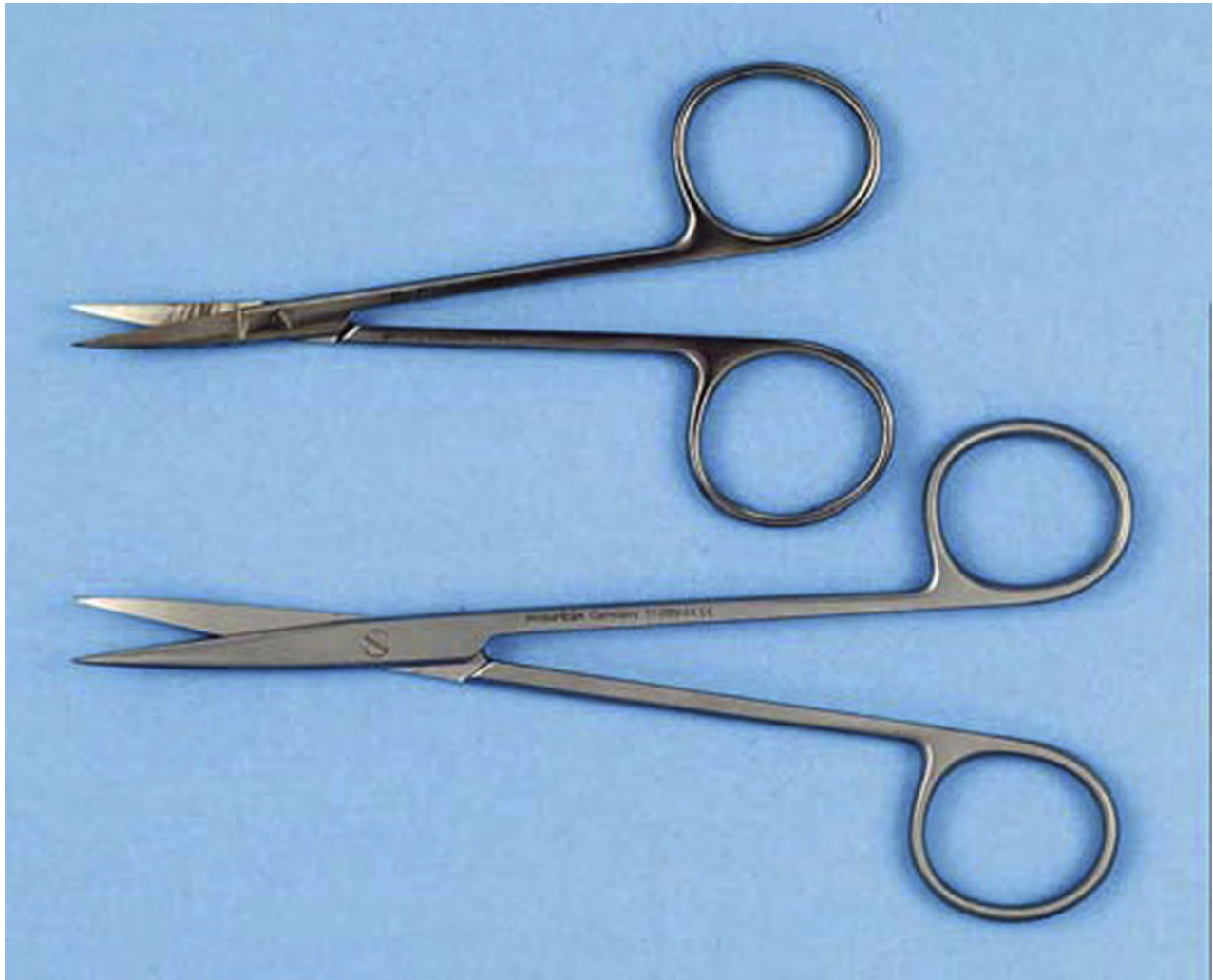print & web 4C/FPO

**FIGURE III-9.** The scalpel is held with a pen grasp to allow maximum control. Reprinted with permission from Hupp<sup>1</sup>.



### *Cutting Soft Tissue (Scissors)*

There are many types of scissors used while performing oral biopsies. They are designed for undermining and cutting soft tissue. Two major types of tissue scissors are iris scissors and Metzenbaum scissors (Fig III-10). These scissors can have straight or curved blades. Iris scissors are small, sharply pointed, delicate tools used for fine work. Metzenbaum scissors are used for undermining soft tissue and for cutting. They can have sharp or blunt (rounded) tips. Tissue scissors such as iris or Metzenbaum scissors should not be used to cut sutures because the suture material will dull the edges of the blades and make them less effective and more traumatic when cutting tissue. Surgical scissors are held in the same manner as needle holders.



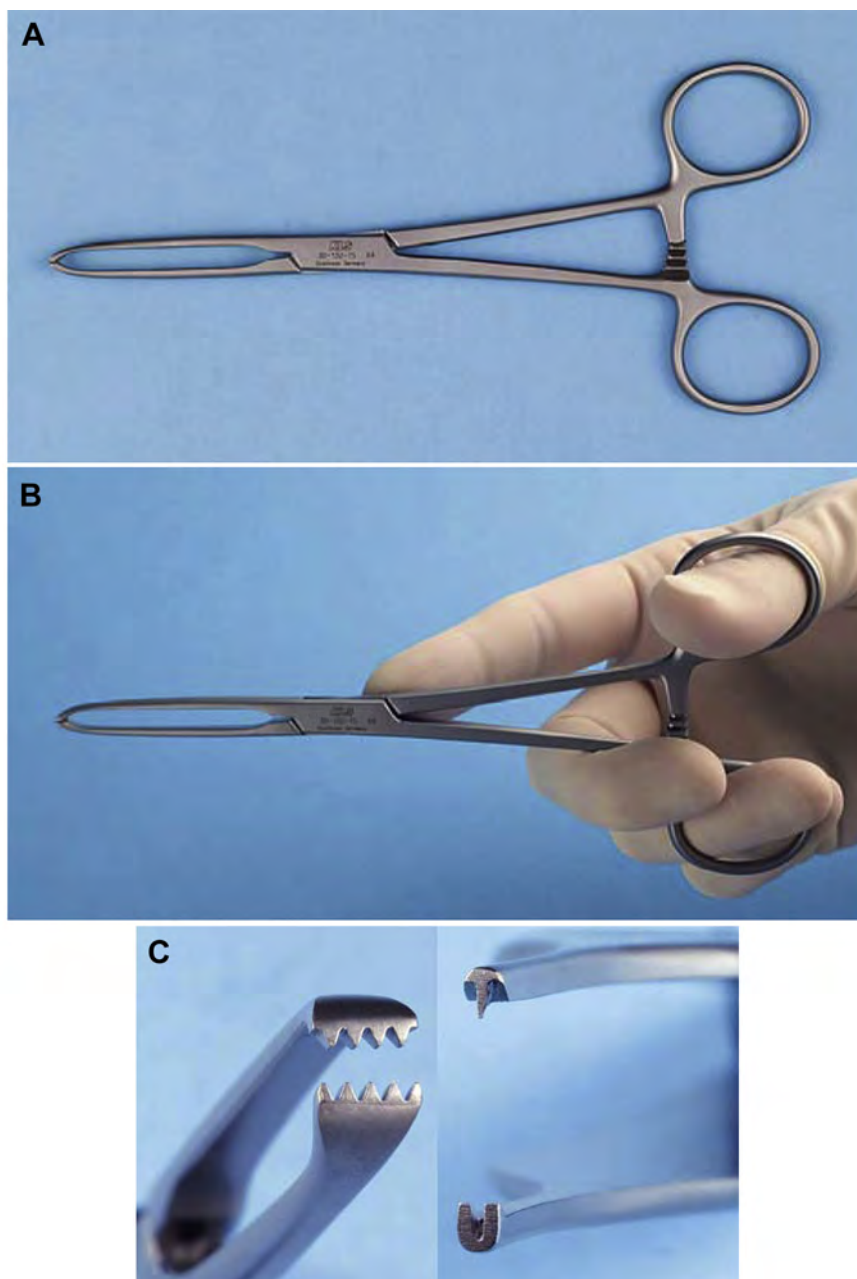
print & web 4C/FPO

**FIGURE III-10.** Soft tissue scissors are of 2 designs. *Top*, Iris scissors are small, sharply pointed scissors with curved blades. *Bottom*, Metzenbaum scissors are longer, delicate scissors. Metzenbaum scissors are available as sharp tipped (*shown here*) or blunt tipped. Reprinted with permission from Hupp<sup>1</sup>.

### Grasping Tissue

Adson forceps (Fig II-5) can be useful when performing a biopsy. They can be used to grasp the tissue to stabilize the lesion while incising and then be used while suturing the resulting open wound.

In some types of biopsies, forceps with locking handles and teeth that will grip the tissue firmly are necessary. In this situation, the Allis tissue forceps are used (Fig III-11A, B). The locking handle allows the forceps to be placed in the proper position and then to be held by an assistant to provide the necessary tension for proper dissection of the tissue. The Allis forceps should never be used on tissue that is to be left in the mouth because they cause a relatively large amount of tissue destruction as a result of crushing injury (Fig III-11C). However, the forceps can be used to grasp the tongue in a manner similar to a towel clamp.



**FIGURE III-11.** A, Allis tissue forceps are useful for grasping and holding tissue that will be excised. B, Allis forceps are held in the same fashion as the needle holder. C, Comparison of Adson beaks (*right*) with Allis beaks (*left*) shows the differences in their designs. Reprinted with permission from Hupp<sup>1</sup>.

## SOFT TISSUE BIOPSY TECHNIQUES

Biopsy of oral soft tissues is a useful competency for a general dentist to possess. When performed properly, most biopsies are straightforward procedures that can be readily performed in the dental office using local anesthesia and minimal instrumentation. The only variables of the technique relate to areas of anatomic risk or limitations imposed by the size and type of lesion.

### ANESTHESIA

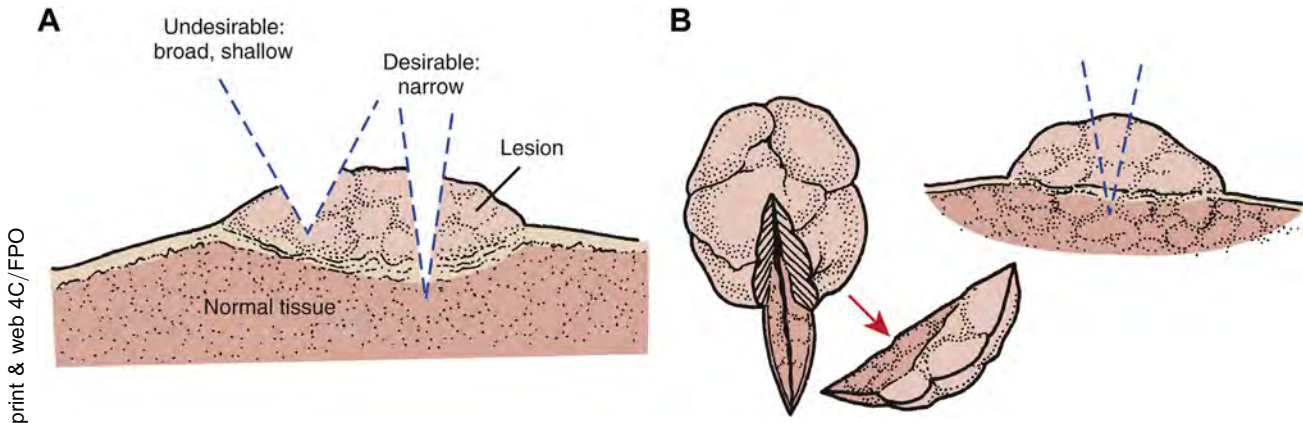
Block local anesthesia techniques are preferred over infiltration, whenever possible, so that the anesthetic solution is not inadvertently incorporated in the surgical specimen. Infiltration anesthesia can cause distortion of the cellular architecture of the specimen and make pathologic diagnosis more difficult, if not impossible. Peripheral infiltration of local anesthetic with a vasoconstrictor is often helpful, injecting at least 1 cm away from the lesion's perimeter to prevent distortion of the lesion itself.

### INCISIONAL BIOPSY

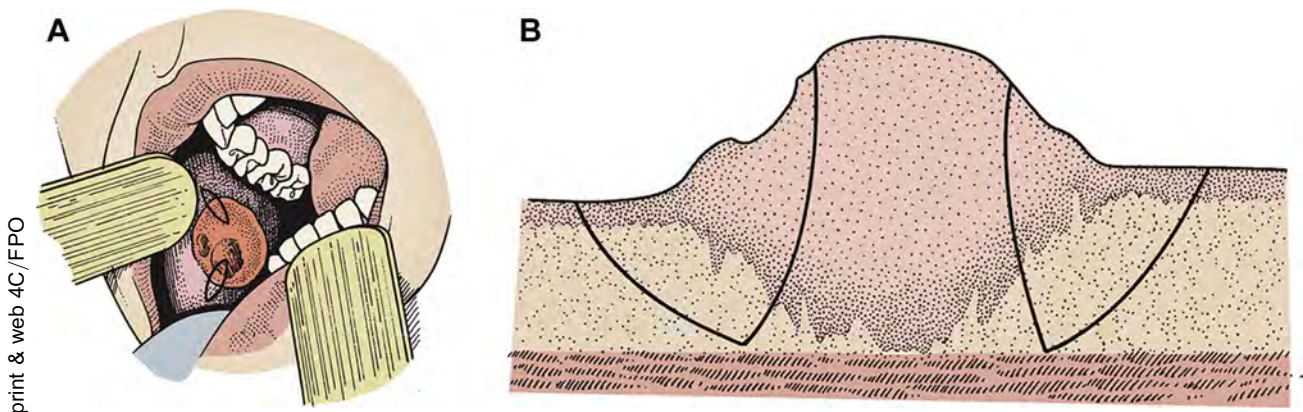
An incisional biopsy is a procedure that removes only a portion of a lesion. If the lesion is large or exhibits differing characteristics in different locations, then more than 1 area of the lesion might require sampling. Incisional biopsies are used when the lesion is large (>1 cm in diameter), is located in a hazardous location, or when a definitive histopathologic diagnosis (eg, for suspected malignancy) is desired before planning a complex removal or other treatment. In larger lesions with variable surface characteristics, an incisional biopsy might be indicated, and occasionally more than 1 sample has to be taken from different areas of the lesion.

The incisional biopsy is generally excised as a wedge of tissues that intentionally includes normal- and abnormal-appearing tissues in the sample (Figs III-12, III-13). The only exception to this approach is when a malignant lesion is strongly suspected. In that circumstance, including normal-appearing tissue in the specimen could spread malignant cells.

Central areas of a large lesion are often necrotic and therefore of little diagnostic value to the pathologist, whereas active growth is taking place at the perimeter; therefore, inclusion of the lesion interface with normal-appearing tissue can exhibit many important cellular changes. Care must be taken to include an adequate depth of tissue, so that cellular features from the base of the lesion are included. In general, it is better to take a narrow, deep specimen rather than a broad, shallow one. Care should be taken not to compromise important adjacent anatomic structures, such as nerves or major ducts or blood vessels, unless they seem to have a relation to the origins or pathology of the lesion.



**FIGURE III-12.** A, Desirability of obtaining a deep specimen, rather than a broad and shallow specimen, when incisional biopsy is performed. If malignant cells are present only at the base of the lesion, then a broad and shallow biopsy might not obtain these diagnostic cells. B, Desirability of obtaining incisional biopsy at the margin of the soft tissue lesion. The junction of the lesion with normal tissue frequently provides the pathologist with more diagnostic information than a biopsy specimen taken only from the center of the lesion. This is particularly important when a biopsy of an ulcer is performed. Reprinted with permission from Hupp<sup>1</sup>.

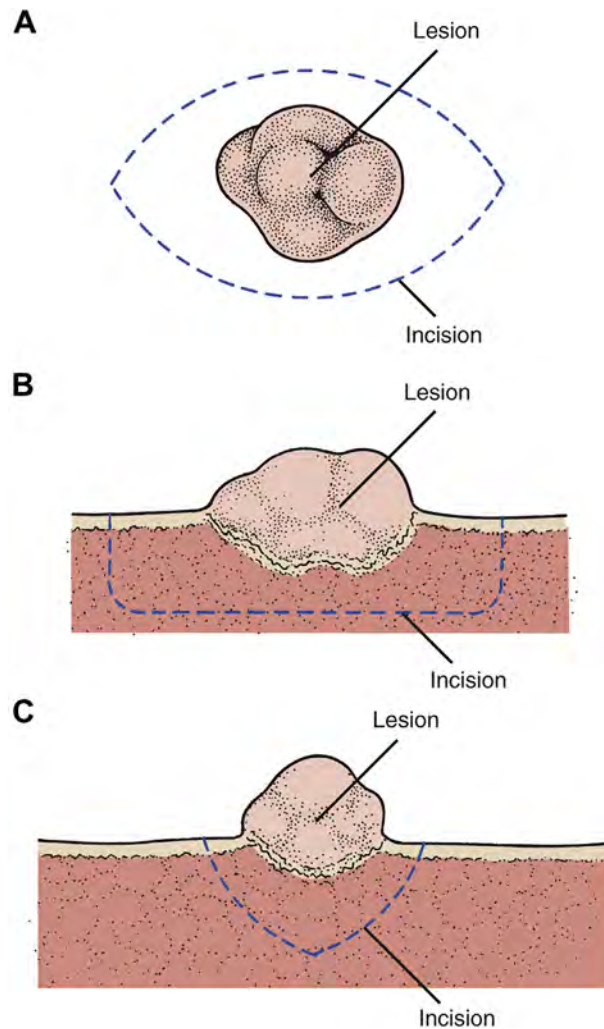


**FIGURE III-13.** A, Frequently, one area of a lesion appears histologically different from another. Therefore, it is often desirable to obtain more than 1 incisional biopsy to detect whether the characteristics of the lesion differ from one area to another. B, When obtaining a biopsy on buccal or labial mucosa, the incision is usually carried to the depth of the musculature. Reprinted with permission from Hupp<sup>1</sup>.



## EXCISIONAL BIOPSY

An excisional biopsy consists of the removal of a lesion in its entirety, to include a 2- to 3-mm perimeter of normal tissue around the lesion (Fig III-14). The width of the perimeter of normal tissue can vary, depending on the presumptive diagnosis. An additional 2 to 3 mm of tissue might be required for specimens suspected of being malignant, including some pigmented lesions and lesions already diagnosed as having dysplastic or malignant cells. Complete excision often constitutes definitive treatment of the lesion biopsied. Excisional biopsy also is reserved for smaller lesions (<1 cm in diameter), taking care to avoid adjacent nerves or blood vessels unless they are thought to be a part of the lesion or the lesion has been determined to be a malignancy.

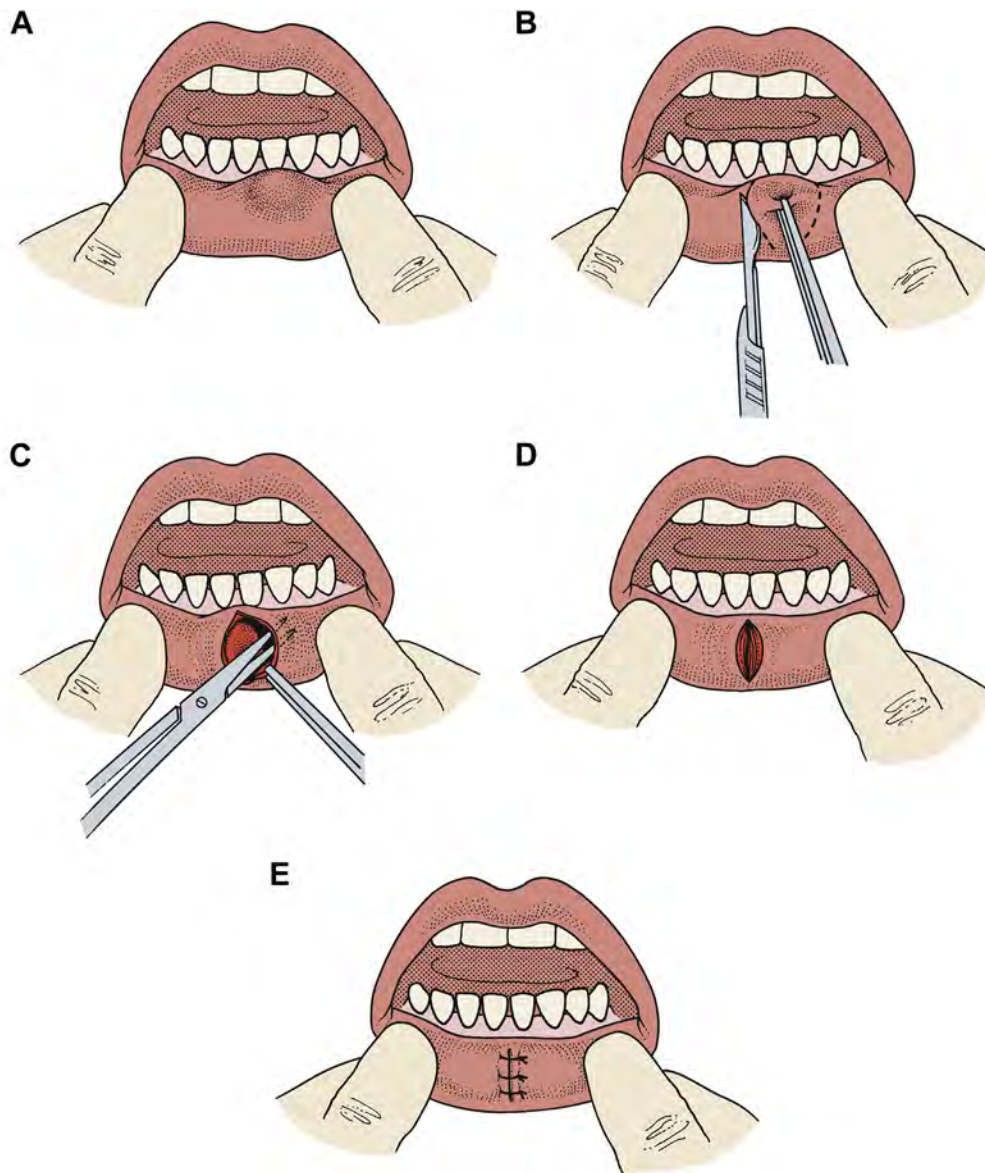


**FIGURE III-14.** Excisional biopsy of soft tissue lesion. *A*, Surface view. An elliptical incision is made around the lesion, at least 3 mm away from the lesion. *B*, Side view. The incision is made deep enough to remove the lesion completely. *C*, End view. Incisions are made convergent to the depth of the wound. An excision performed this way facilitates closure. Reprinted with permission from Hupp<sup>1</sup>.



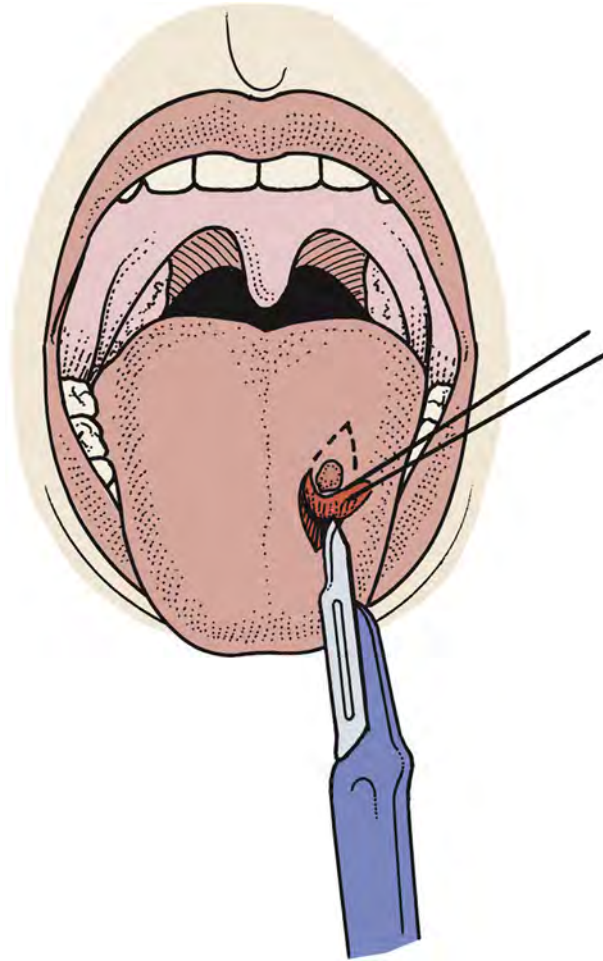
## TISSUE STABILIZATION

Oral soft tissue biopsies frequently involve mobile surfaces and structures (eg, lip, cheek, and tongue). Accurate surgical incisions can be placed with greater ease when the involved tissues are first stabilized. This can be accomplished by any of several methods. The surgical assistant can grasp the lip on both sides of the biopsy site with his or her fingers, which also retracts and immobilizes the lip (Fig III-15). This also can help decrease bleeding by compressing labial blood vessels and their tributaries. The surgeon must be careful to avoid iatrogenic scalpel injury to the assistant's stabilizing fingers. Different retractors are available that can perform the same function.



**FIGURE III-15.** Examples of methods to stabilize tissue for biopsy. *A*, The assistant's fingers are used to stabilize the tissue before excisional biopsy of a probable mucocele. *B*, An elliptical incision is made around the lesion while stabilizing the tissue with Adson forceps. *C*, The surgeon dissects around the involved minor salivary gland with soft tissues scissors. *D*, *E*, The resulting mucosal wound is undermined and closed. Reprinted with permission from Hupp<sup>1</sup>.

When used, retraction sutures should be placed deeply into the tissues, away from the planned biopsy site, so that they can function without pulling through or damaging the tissues (Fig III-16). As mentioned earlier, Adson or Allis forceps can be used to provide tissue stabilization.



print & web 4C/FPO

**FIGURE III-16.** Use of traction suture placed through the specimen. While the lesion is incised, a traction suture is used to lift the specimen from the wound bed. Then, the suture can be tied and left attached to the lesion to identify the orientation of the specimen. Reprinted with permission from Hupp<sup>1</sup>.

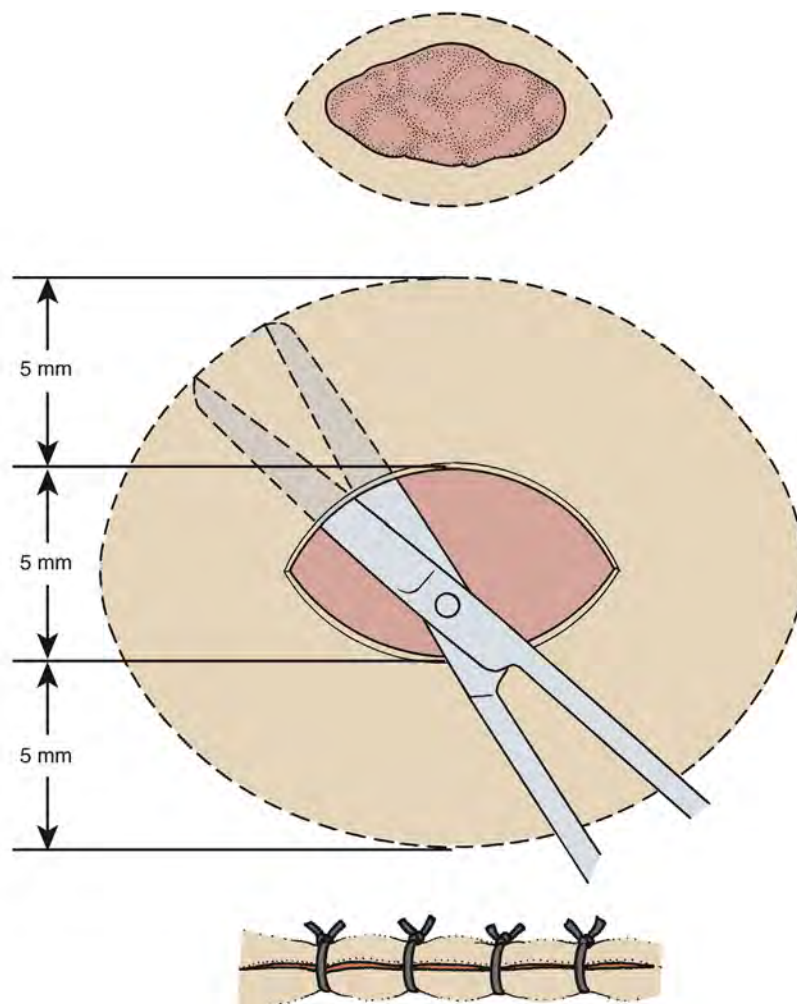
#### HEMOSTASIS

The use of a suction device for keeping the surgical field free of blood during the procedure should be minimized as much as possible, especially high-volume suction devices found in modern dental offices. The assistant can usually use gauze sponges to blot the site during the procedure. Suctioning can increase not only bleeding but also the risk of the biopsy tissue sample being accidentally aspirated into the suction. If suction is needed, it is helpful to place gauze over the end of the suction tip to serve as a filter.

## WOUND CLOSURE

After removal of the tissue sample, primary closure of the wound is desirable and usually possible. If the wound is deep, thus incorporating different tissue layers, deep closure should be carried out using a resorbable suture material (eg, polyglycolic acid or chromic gut).

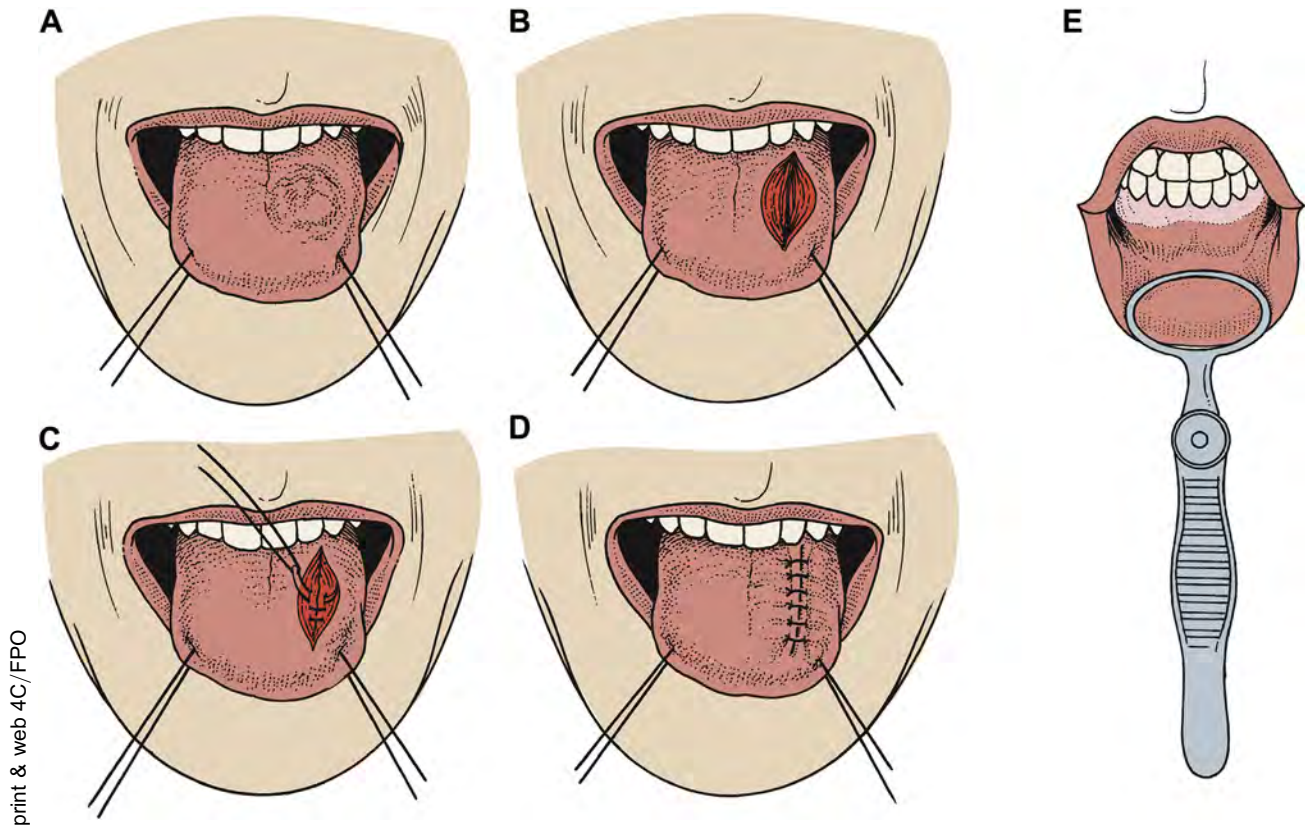
The wound left after a larger biopsy often will not close without tension on the wound edges. Undermining of adjacent surface tissue is used to help decrease the tension on wound edges during closure. Mucosa is undermined by using a spreading action of the tips of small scissors (eg, iris or Metzenbaum scissors) to separate the mucosal from the submucosal tissues (Fig III-17). The submucosal layer is largely loose connective tissue that is easily dissected free from the overlying mucosa without sharp incision or snipping. This permits closure of the mucosa as a separate layer without regard to closure of the deeper layers. The extent to which this undermining is carried out is determined by the size of the wound and the anatomic location. Undermining permits tension-free approximation of tissue margins. Suture materials of choice are generally black silk or a resorbable material. Biopsy wounds on the dorsum or lateral border of the tongue require deeply placed sutures at close intervals to counteract inherent muscle movements and maintain closure.



print & web 4C/FPO

**FIGURE III-17.** The principles used in closing an elliptical biopsy wound. The mucosa should be undermined bluntly with scissors to the width of the original ellipse in each direction. Scissors are inserted under mucosa tissue while closed and then opened to spread tissues, undermining the mucosa in that area. This is repeated around the periphery of the wound. This allows approximation of wound margins without tension. Reprinted with permission from Hupp<sup>1</sup>.

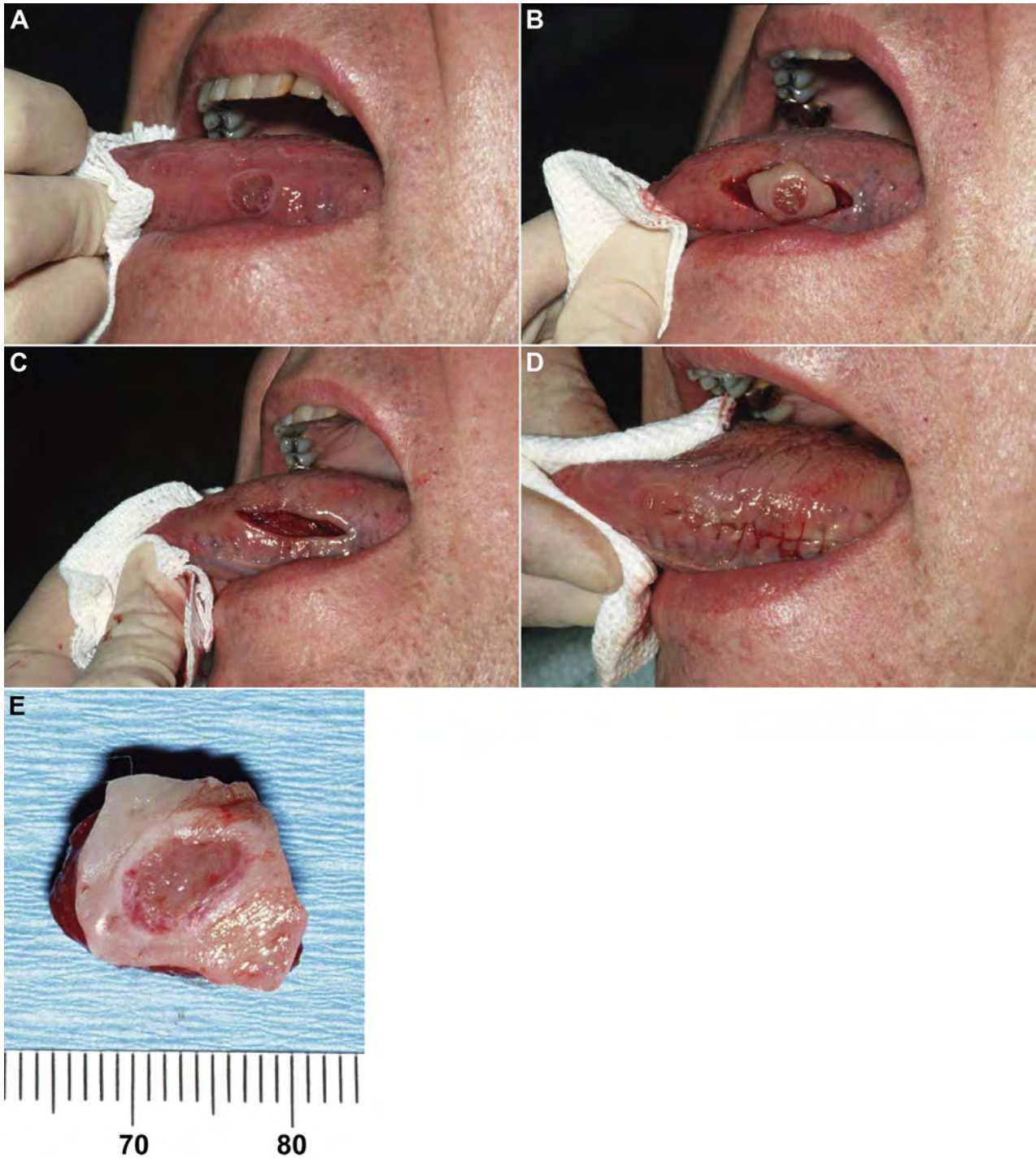
Resorbable sutures can be used, but gut sutures are not recommended because they might have poor knot security (resulting in lost sutures) and undergo rapid enzymatic degradation. Examples of tongue biopsies are shown in [Figures III-18 and III-19](#).



print & web 4C/FPO

**FIGURE III-18.** Stabilization of tongue for biopsy. *A*, Stabilization of tissue with traction sutures. Two silk sutures are used to stabilize the tongue before excisional biopsy. They are placed through the substance of the tongue (mucosa and muscle) to prevent pulling through tissue. *B*, The lesion is removed after an elliptical incision has been made around it. *C*, Resorbable sutures are placed to approximate muscle. *D*, The mucosa is closed. *E*, Alternative means of stabilization of tissue using a chalazion-type device. Reprinted with permission from Hupp<sup>1</sup>.





print & web 4C/FPO

**FIGURE III-19.** *A*, Excisional biopsy of a tongue ulcer. *B*, Elliptical incisions are made around the lesion, with 2 to 3 mm of normal tissue included. *C*, Appearance after the specimen has been removed and the muscle has been sutured. Note that the deep sutures have made an almost linear closure of the mucosa possible. *D*, Appearance after mucosal closure. *E*, Specimen. Reprinted with permission from Hupp<sup>1</sup>.



## HANDLING THE SPECIMEN

Any tissue specimen must be maintained in a condition that is optimal for preserving the histologic and structural architecture of the cells of the lesion. Specimens that have been crushed, frozen, desiccated, burned, or otherwise compromised might not be microscopically diagnostic once they reach the oral and maxillofacial pathologist, necessitating a repeat biopsy (which might or might not be feasible). Extreme care should be exercised when removing surgical specimens to avoid instrument damage to the specimen during manipulation. The removed tissue sample should not be wrapped in gauze (wet or dry) because it is at risk of getting thrown out accidentally with the gauze. The specimen also should not be set on paper or linen drapes and allowed to dry out while the surgery is being completed. Rather, the specimen should be placed immediately in a glass or plastic container that contains a quantity of 10% formalin solution (4% formaldehyde) that is at least 20 times the volume of the specimen itself and that can be capped (Fig III-20). The specimen must be totally immersed in the preservative solution at all times, even if the container is tilted sideways during transport. Before turning attention to wound closure, the dentist should ensure that the tissue sample does not adhere to the container wall above the level of the formalin. If the specimen is mailed to the pathologist, then it must be labeled with a biohazard label approved by the Occupational Safety and Health Administration; if the specimen is transported internally (eg, within a hospital), such labeling is not always mandated.



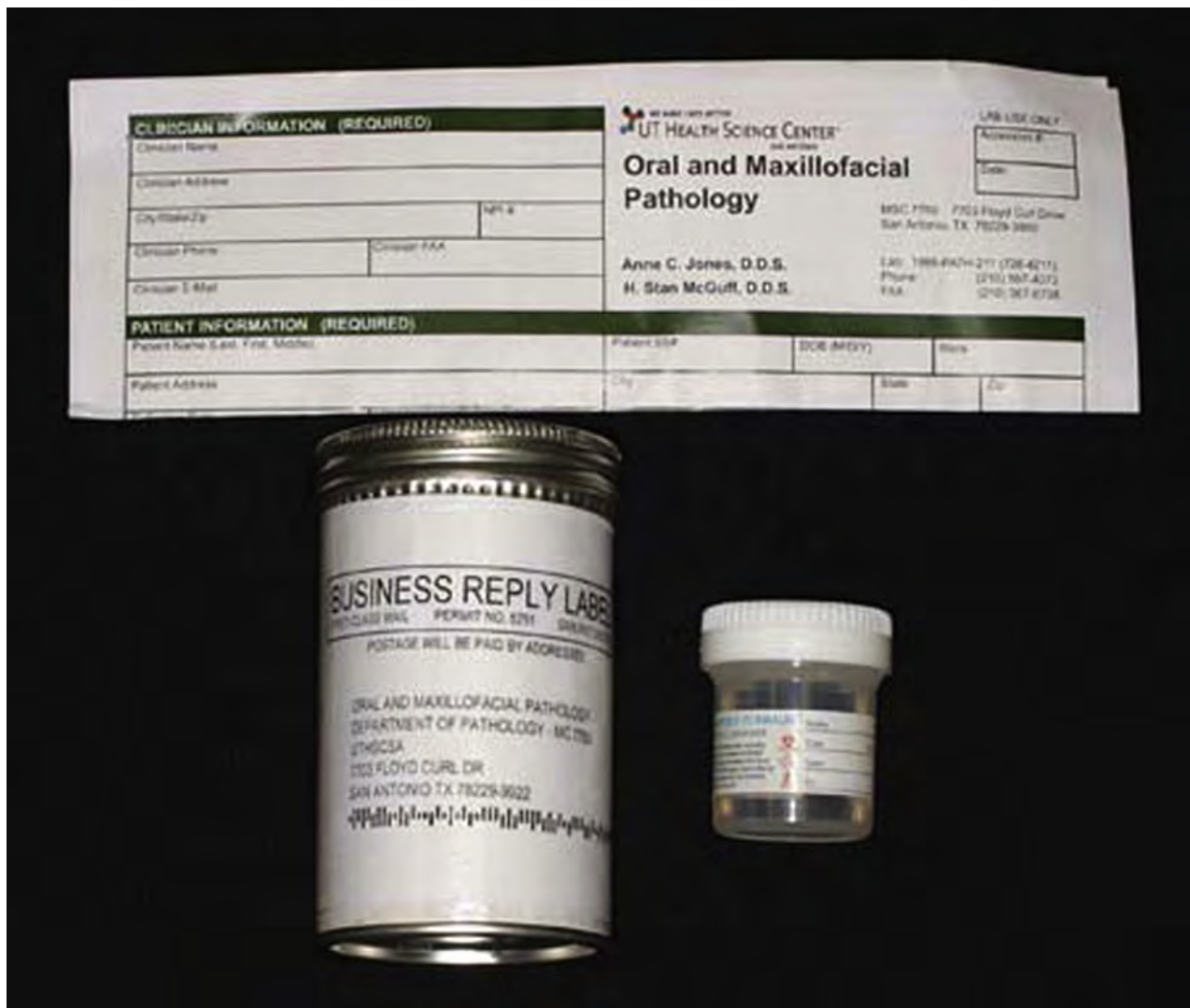
print &amp; web 4C/FPO

**FIGURE III-20.** A specimen being dropped into a biopsy bottle filled with formalin. Do not re-enter the wound with the forceps unless they are first rinsed free of the fixative solution. Reprinted with permission from Hupp<sup>1</sup>.

## TAGGING OF SPECIMENS

If dysplasia or malignancy is suspected, it is helpful to the pathologist if the surgeon “tags” one of the margins of a specimen with a loosely tied suture to orient the anatomic alignment of the specimen. This allows the pathologist to report precisely which specific margins or areas, if any, require wider or deeper excision. The orientation and location of the marker suture should be illustrated, documented, or both on the oral and maxillofacial pathology service’s submission form (Fig III-16).

Suture tagging also can be used to identify multiple specimens from 1 lesion when accompanied by a drawing that delineates from which area each specimen was removed and the orientation of each specimen. The first specimen receives 1 tagging suture and the second receives 2, and so on, for all other specimens. However, each specimen should be submitted in its own container (Fig III-21).



print &amp; web 4C/FPO

**FIGURE III-21.** Typical biopsy kit that is available from pathology laboratories. The kit includes a specimen bottle containing formalin, a biopsy requisition form onto which information about the patient and specimen is documented, and a mailer to send the specimen back to the laboratory. Reprinted with permission from Hupp<sup>1</sup>.

## SUBMISSION OF SPECIMENS

Every dental office should prearrange a relationship with a local or regional oral and maxillofacial pathology examination service where specimens can be submitted. In general, it is preferable to have odontogenic tissues submitted to an oral and maxillofacial pathologist, whenever possible. Highly competent, general (medical) pathologists might not be familiar with the subtleties of odontogenic cysts and tumors, which occasionally can result in incorrect diagnoses and treatment. If the city or town in which the dental office is located does not have such a service available, then many dental schools and oral and maxillofacial pathology practices in most major cities might offer a mail-based service and provide the dental office, on request, with mailing kits that can be used for submissions. Mailed specimen containers should contain a form with detailed information and a capped, biohazard-labeled container (usually glass or plastic) with an appropriate amount of formalin that is labeled with the address of the pathology service. The patient's name and the referring dentist's name also should be entered on the specimen bottle label in case the outer mailing container is damaged in transit and the bottle becomes separated from it (Fig III-21).

## BIOPSY SUBMISSION FORM

Each pathology laboratory has a form unique to its facility for use in submitting specimens for examination (Fig III-22). As noted earlier, the specimen container must be labeled and identified with the demographic data of the patient and the name and address of the submitting dentist in the event it gets separated from the submission form, transporting container, or both. Most forms are structured to gather supporting information and data, which generally include demographic data about the patient; name and contact information for the submitting dentist; pertinent medical, family, social, and lesion histories; clinical description of the lesion, specimen, or both; and presumptive clinical differential diagnoses. The dentist must take the time to provide as much information on the submission form as possible to aid the pathologist. Insufficient information, incomplete data, or important omitted historical notes often lead to wasted time and inaccurate diagnoses.

Most pathology laboratories send the written microscopic examination report to the referring dentist within 7 to 14 days after receipt of the specimen. The dentist should plan to see the patient in approximately 1 week to remove sutures and counsel the patient on the biopsy results, if available. If the result is not yet received, then the dentist could elect to call the patient at home (if the report is negative for malignancy, documenting the call in the patient record) or have the patient return 2 weeks after surgery (if the microscopic diagnosis is one of malignancy) to discuss the results in person with the patient and arrange for timely referral appointments. As noted earlier, patients who must be informed of adverse diagnoses (eg, cancer) should be counseled with great sensitivity to counteract possible anxiety or depression over the diagnosis. At the same time, the importance of early treatment and close follow-up must be emphasized. Delays in beginning treatment (procrastination) can seriously worsen the prognosis of many lesions, so it is important to arrange prompt referral for such patients to specialists with the ability to manage their conditions.

A negative (benign) pathology report should never be taken as a final assessment, and the dentist should not be lulled into a false sense of security when one is received. If the clinical behavior of a lesion suggests that it is not benign, a second biopsy of the area should be considered. Moreover, a nondiagnostic or unrepresentative area of the lesion might have been sampled, and the areas of pathologic cellular changes might not have been included in the specimen(s). Errors in microscopic diagnosis also occur, especially if odontogenic tissues are examined by general pathologists who might be unfamiliar with the nuances of oral and odontogenic lesions. It is not inappropriate in such cases to ask for a second pathology opinion from an oral and maxillofacial pathologist before contemplating ablative or disfiguring surgery. General dentists who submit biopsies also must be conversant with the terminology used in reports to fully grasp the meaning of the microscopic diagnosis and the course of treatment or follow-up that is appropriate for that diagnosis. If any uncertainty about the contents of the report exists, then the dentist should seek clarifications from the pathologist.



## POSTBIOPSY MONITORING

After an incisional biopsy for diagnosis, a positive pathology report (indicating dysplastic changes or malignancy) generally mandates appropriate surgical excision of the lesion and contiguous tissues as indicated by the histopathologic diagnosis. This might necessitate referral to an oral and maxillofacial surgeon or other head and neck specialist who is experienced in the management of malignancies. However, a negative biopsy report should never be taken at face value, but should be interpreted with clinical and historical findings in mind. If doubt exists, a second biopsy might be indicated. At the very least, plans should be developed for a structured schedule of continued close observation at appropriate intervals. In general, it is prudent to re-examine the patient within 1 month and then at 3, 6, and 12 months during the first year. Thereafter, if clinical and radiographic findings are unchanged, the interval between follow-up visits can be increased to 6 and then 12 months, as appropriate. Patients should always be counseled to contact the dentist immediately if any clinical changes or new symptoms are noted between visits.

## Reference

1. Hupp JR, Ellis III E, Tucker MR: Contemporary Oral And Maxillofacial Surgery (ed 6). St. Louis, MO, Elsevier, 2014



## Section IV Postoperative Medications

Once an oral surgical procedure is complete, the dentist must determine whether a prescription medication is indicated. In addition, in cases with an indication for preoperative antibiotic prophylaxis, the dentist will need to write a prescription for the patient. This section discusses the protocol for writing a prescription, with several examples. The section will then discuss the commonly prescribed drugs used by dentists before and after surgery.

Note that the information in this section is a short summary of the information dentists must know to properly use these drugs and prescribe. It is not intended to substitute for a more comprehensive pharmacology course on the topics of analgesics and antibiotics.

### Prescriptions for Drugs

Drugs that carry significant side effects, toxicities, or abuse potential are usually only available by prescription. Therefore, when the dentist needs to give such drugs to a patient, the doctor must “write” a prescription. Whether in hard copy or electronically created and transmitted, prescriptions have a standardized format.

Most practices and institutions have their official name, address, and telephone number at the top of the prescription. This is then followed by blank lines designated for entering the patient’s name, the date, and the patient’s address. Next, the doctor enters the name of the prescribed drug, the unit dosage, the number of doses, and the dosing instructions. These will appear on the label of the drug container dispensed by the pharmacy. Close to the bottom of the prescription is a line for the doctor to sign. On some forms, the line the doctor signs signifies whether the pharmacist filling the prescription may or may not substitute a generic drug for a brand name drug, if the doctor wrote for a brand name drug. A blank line is available for the doctor to enter their Drug Enforcement Agency (DEA) number when required. The number of refills allowed by the prescriber for that particular prescription can also appear on the prescription form (examples can be seen in [Fig IV-1](#)).

print & web 4C/FPO

<p>Don Carlos Buell, DMD 1825 Battlefield Road Perryville, KY 40468 (859) 555-8631</p> <hr/> <p>Name <u>Braxton Bragg</u> Date <u>10/8/12</u> Address <u>207 Polk St., Perryville, KY</u></p> <p>Amoxicillin 500mg Disp: 4 caps Sig: 4 caps at 8:00 am</p> <p>Refill <del>0-1-2-3</del> <u>Don Carlos Buell</u> DMD DEA No _____</p>	<p>Don Carlos Buell, DMD 1825 Battlefield Road Perryville, KY 40468 (859) 555-8631</p> <hr/> <p>Name <u>Braxton Bragg</u> Date <u>10/8/12</u> Address <u>207 Polk St., Perryville, KY</u></p> <p>Aspirin 325 mg <math>\bar{c}</math> 5 mg Oxycodone Disp: 12 (twelve) tabs Sig: One tab q 4 h prn pain. Take with food.</p> <p>Refill <del>0-1-2-3</del> <u>Don Carlos Buell</u> DMD DEA No <u>CBxxxxxxx</u></p>
<p>Don Carlos Buell, DMD 1825 Battlefield Road Perryville, KY 40468 (859) 555-8631</p> <hr/> <p>Name <u>Braxton Bragg</u> Date <u>10/8/12</u> Address <u>207 Polk St., Perryville, KY</u></p> <p>Penicillin V 500mg Disp: 28 tabs Sig: 1 tab qid until gone</p> <p>Refill <del>0-1-2-3</del> <u>Don Carlos Buell</u> DMD DEA No _____</p>	<p>Don Carlos Buell, DMD 1825 Battlefield Road Perryville, KY 40468 (859) 555-8631</p> <hr/> <p>Name <u>Braxton Bragg</u> Date <u>10/8/12</u> Address <u>207 Polk St., Perryville, KY</u></p> <p>Tylenol # 3 Disp: 18 (eighteen) caps Sig: One cap q 4 h prn pain. Take with food</p> <p>Refill <del>0-1-2-3</del> <u>Don Carlos Buell</u> DMD DEA No <u>CBxxxxxxx</u></p>

**FIGURE IV-1.** Four examples of prescriptions written for antibiotics and analgesics. Reprinted with permission from Hupp<sup>1</sup>.

## Antibiotic Overview

### PENICILLINS

The penicillin family, including primarily penicillin V and amoxicillin, has long been the mainstay in the antibiotic treatment and prevention of odontogenic infections. (Note that the correct generic name of phenoxy-methyl penicillin potassium is penicillin V. It is not penicillin VK.) Randomized controlled clinical trials comparing one penicillin with other, newer antibiotics have found no statistically significant differences in the clinical cure rates.

The antibacterial spectrum of penicillin includes the gram-positive cocci (except for staphylococci) and oral anaerobes. Penicillin G is given parenterally, and penicillin V and amoxicillin are preferred for oral administration. The penicillins have little toxicity, except for allergic reactions, which occur in about 3% of the population.

Amoxicillin and ampicillin are semisynthetic penicillins that are more effective against gram-negative rods than is penicillin. Amoxicillin has the advantage of a longer serum half-life than ampicillin and penicillin, making its effective duration and its dosage interval longer. Recently, the costs of amoxicillin and penicillin have become quite comparable. Although both penicillin and amoxicillin are effective in treating odontogenic infections, amoxicillin is often preferred to penicillin because its longer dosage interval improves patient compliance. Amoxicillin is given 3 times per day; penicillin V and ampicillin are given 4 times per day.

Penicillinase-resistant penicillins, such as methicillin and dicloxacillin, were effective in the past for penicillinase-producing staphylococci. Because more than 85% of staphylococcus strains, especially methicillin-resistant *Staphylococcus aureus*, have become resistant to this class of penicillins, their usefulness has diminished.

### CEPHALOSPORINS

Cephalosporins are a group of  $\beta$ -lactam antibiotics that are effective against gram-positive cocci and many gram-negative rods. A large number of cephalosporins are available and are roughly divided into 4 generations on the basis of their activity against gram-negative organisms. First-generation cephalosporins have a similar activity to penicillin, including activity against gram-positive cocci and some strains of gram-negative bacteria such as *Escherichia coli*, *Klebsiella*, and *Proteus mirabilis*. First-generation cephalosporins, however, are not as effective against oral anaerobes as are the penicillins.

Second-generation cephalosporins have broader activity against gram-negative bacteria and increased activity against anaerobic bacteria. The second generation has less activity against gram-positive cocci compared with the first generation.

Third-generation cephalosporins are much more active against enteric gram-negative rods but are decidedly less active than first- and second-generation cephalosporins against gram-positive cocci.

Fourth-generation cephalosporins are designed to be effective against enteric gram-negative rods, especially *Pseudomonas aeruginosa*, which is not generally encountered in odontogenic infections.

Two oral cephalosporins are effective in odontogenic infections: 1) cephalexin and 2) cefadroxil. Although neither of these is the drug of first choice for treating odontogenic infections, they can be useful in certain situations in which a bactericidal antibiotic is necessary and the first-line antibiotics cannot be used.

The toxicity of the cephalosporin group is primarily related to allergy. Patients who are allergic to penicillin drugs should be given cephalosporin antibiotics with caution. Patients who have had anaphylactic reactions (ie, hives, angioneurotic edema, respiratory distress, shock, or all of these) in response to any of the penicillins should not be given cephalosporins.

### CLINDAMYCIN

The antibacterial spectrum of clindamycin includes gram-positive cocci and almost all anaerobic bacteria. Clindamycin is effective against streptococci, some staphylococci, and anaerobes. The drug is 4 to 5 times more expensive than penicillin, and the increasing clindamycin resistance rates of oral streptococci are of concern. Therefore, clindamycin is best used for therapeutic and prophylactic indications only in penicillin-allergic patients.

Antibiotic-associated colitis, resulting in persistent and possibly life-threatening diarrhea, has been associated with clindamycin, but is actually more commonly seen with the use of other antibiotics including ampicillin. Its cause has been identified as the elaboration of an exotoxin by *Clostridium difficile*. It most typically occurs in

medically debilitated patients. After diagnosis based on a stool assay for the *C. difficile* exotoxin, the treatment includes antibiotic therapy with oral vancomycin or metronidazole.

#### METRONIDAZOLE

Metronidazole is only effective against obligate anaerobic bacteria. It has no effect on bacteria that are aerobic or facultative (growing both in the presence and in the absence of oxygen). Most oral streptococci are facultative and, thus, resistant to metronidazole. Conversely, the oral *Prevotella* and *Porphyromonas* bacteria are obligate anaerobes; they are sensitive to metronidazole. This antibiotic is sometimes used in periodontal disease therapy; it can also be useful in the management of anaerobic odontogenic infections alone or combined with other antibiotics such as penicillin.

#### MACROLIDES (ERYTHROMYCIN FAMILY)

Older macrolide antibiotics, such as erythromycin, have lost much of their effectiveness against the main pathogens of odontogenic infections, oral streptococci, and oral anaerobes. This family of antibiotics has also had significant disadvantages because of gastrointestinal intolerance and frequent drug interactions, involving the liver microsomal enzymes responsible for the metabolism of many drugs and foods.

Azithromycin is a member of the macrolide family that has been shown to be effective against odontogenic infections when combined with appropriate surgery. It is also better tolerated by the gastrointestinal tract. Its metabolism involves a slightly different pathway from those of other macrolides, eliminating most of the drug interactions commonly seen with the macrolides. Azithromycin can be a good antibiotic choice in patients who can tolerate neither penicillins nor clindamycin.

#### TETRACYCLINES

Tetracyclines are available for oral and parenteral administration and are generally considered broad-spectrum antibiotics. However, bacterial resistance to these drugs is common. Tetracyclines are considered clinically useful only against anaerobic bacteria, and this is the basis for their use in odontogenic infections. Tetracycline has become an expensive drug to use compared with other more effective antibiotics used for odontogenic infections.

The toxicities of tetracyclines are generally low but include staining of developing teeth if given to children or to pregnant or lactating women. Doxycycline is preferred because it is taken only once daily, which improves patient compliance.

Tetracyclines have an anticollagenase effect. This activity can make them useful for treatment of periodontal and peri-implant disease. This has prompted the use of topical preparations of tetracyclines placed into periodontal pockets and for the prevention of dry sockets.

#### FLUOROQUINOLONES

This family of antibiotics includes ciprofloxacin, levofloxacin, and moxifloxacin. Fluoroquinolones are broad-spectrum, bactericidal, orally taken antibiotics. The first 2 generations of the fluoroquinolone drugs are only marginally effective against streptococci and have little or no effect against anaerobic bacteria.

Moxifloxacin, however, is a fourth-generation\* fluoroquinolone that is effective against oral streptococci and anaerobes. However, it has multiple side effects, including toxicity to developing cartilage, muscle weakness, and drug interactions that can be fatal. Similar to the other fluoroquinolones, therefore, moxifloxacin should be avoided in persons younger than 18 years of age and in combination with multiple other drugs. The fluoroquinolones are used only with caution when first-line antibiotics cannot be used.

#### ANTIFUNGAL DRUGS

Mucosal candidiasis, or oral thrush, should be treated with the topical application of antifungal agents. The 2 antibiotics of choice are nystatin and clotrimazole. Both drugs are available as lozenges that are held in the mouth until they dissolve. The patient should use 1 lozenge 4 to 5 times daily for 10 days for effective control and to prevent relapse of the candidiasis. Clotrimazole is often better tolerated because of its more pleasant taste.

---

\*A fifth generation of cephalosporins is sometimes designated.

Newer azole antifungal agents such as fluconazole, itraconazole, and voriconazole are generally reserved for immunocompromised patients because of their effectiveness against resistant fungi, potentially severe drug interactions, and significantly greater cost. Even newer antifungal antibiotics such as the echinocandins and lipid-based amphotericin preparations are similarly reserved for treating systemic fungal infections in severely immunocompromised patients such as those who have undergone bone marrow transplantation and those with acquired immunodeficiency syndrome.

## **Analgesic Medications**

Most oral surgical procedures produce some degree of postoperative discomfort. Just as with all forms of pain, the patient's perception of the magnitude of their pain varies according to their preoperative expectations in response to previous experiences or the reports of others, their level of anxiety, cultural factors, and environmental distractions (or lack thereof). The surgeon can help modulate the patient's perception of pain through perioperative reassurances and the use of anxiety reduction measures. Anxiety control in the postoperative period depends greatly on providing the patient with accurate information about what to expect and how to manage the probable sequelae and possible complications.

The goal of postoperative pain control should not be the total elimination of patient discomfort. To prevent all postprocedure pain would often require overly high dosages of analgesic medications, raising the risks of side effects. Therefore, the dentist should explain to the patient that the recommended drugs should only be used to reduce postoperative discomfort to a tolerable level. This will help the patient understand what the goal is and to properly self-medicate following their doctor's guidance.

Most routine extractions not requiring a flap or bony surgery produce minimal postoperative discomfort. Therefore, patients should be reassured that they are likely to have limited discomfort once their local anesthesia has abated. In most cases, the discomfort they experience will be self-limiting and well managed with nonprescription (non-narcotic) analgesics such as ibuprofen and acetaminophen. Some practitioners also have patients use ice packs as a method to decrease discomfort (a bag of frozen peas can serve as a useful substitute for ice packs, because they can conform to the face and be refrozen for reuse).

Many clinicians have found that preemptive analgesic administration works well to decrease postoperative discomfort and thereby eliminate or lessen the need for narcotic analgesics. An example of such a protocol follows:

Perioperative preemptive pain management protocol for adult patients (age >12 years, weight >50 kg) who can safely take nonsteroidal anti-inflammatory drugs.

For use when routine extractions are planned.

600 mg ibuprofen 2 hours before the appointment

600 mg ibuprofen within 2 hours after surgery

600 mg every 8 hours thereafter for 48 hours, or longer if needed

Prescriptions for narcotic-containing medications are sometimes required after oral surgery. This is particularly true if flaps and bone removal were necessary or a particularly extensive procedure was performed. Because the analgesic actions of the commonly used narcotics are additive to the commonly used non-narcotic analgesics, dentists typically prescribe analgesic compounds. These compounds contain both a narcotic and non-narcotic analgesic, helping to diminish the amount of narcotic required to achieve pain relief.

Narcotics are wonderful medications when needed and used appropriately. They decrease the pain to tolerable levels without excess sedation. Narcotics are usually effective cough suppressants. Opiates do have side effects that should temper their use. Most narcotics can produce nausea that can lead to vomiting. This side effect is lessened if the patient has eaten before taking the drug, and this instruction can be placed on the prescription label. Narcotic drugs also tend to cause constipation. Given in higher doses, opiates can cause respiratory depression. In addition, giving narcotics for a long period can lead to overuse and eventually dependency. Also, narcotics given to someone previously addicted to them can lead to a relapse into addiction. Narcotic drugs also carry the risk of misappropriation; namely, some patients might sell their prescription opiates to others who are illegally using them.



## COMMONLY USED ANALGESICS IN GENERAL DENTISTRY

*Ibuprofen*

Ibuprofen is a frequently used non-narcotic analgesic to manage mild to moderate postoperative discomfort. Because it is a nonsteroidal anti-inflammatory drug (NSAID), it also helps control inflammation-instigated pain and tissue swelling. Similar to other NSAIDs, ibuprofen alters platelet function, which might then interfere with coagulation. However, it has been shown that for most patients, the amount of platelet inhibition is insufficient to cause a clinically significant effect on postextraction clot formation. NSAIDs do cause stomach irritation; therefore, they are often not recommended for patients with acid-related gastric and esophageal disorders. Also, just as with all NSAIDs, they should not be used in patients with an allergy to any NSAID or in patients with NSAID-induced asthma.

Over-the-counter ibuprofen is inexpensive, especially the private label brands, and typically comes in 200-mg tablets or capsules. The usual effective analgesic dose for average size adults is 600 mg, given no more often than every 4 hours. Ibuprofen can have a toxic effect on the kidneys if taken at too high a dose or for an extended period. The maximum daily dosage of ibuprofen in adults is 3200mg.

*Acetaminophen*

Acetaminophen is another commonly used non-narcotic analgesic. Because it is not an NSAID, it has no anti-inflammatory properties and does not interfere with platelet function. It can help treat a fever. The primary risk for acetaminophen relates to adverse effects on the liver. Therefore, it should not be used in patients with jeopardized liver function, especially those with alcoholic liver disease.

Over-the-counter acetaminophen is inexpensive, especially the private label brands, and typically comes in 325-mg and 500-mg tablets or capsules. The usual effective analgesic dose for average size adults is 500 to 650 mg, given no more often than every 4 hours.

*Codeine*

Although available over-the-counter in other countries, in particular, for its ability to suppress coughing, in the United States, codeine is only available by prescription. Its primary use is as an adjunctive opioid analgesic compounded with other non-narcotic analgesics such as acetaminophen. The most commonly used compound in the United States contains codeine 30 mg and acetaminophen 300 mg. Codeine is a useful drug in dentistry because of its effectiveness and very low abuse potential. However, many patients claim an allergy to codeine owing to the gastric upset they experienced from its use in the past. However, codeine is not different than other narcotic drugs taken orally in that they will all commonly cause nausea if taken on an empty stomach. Therefore, whenever prescribing a narcotic to control postoperative discomfort, it is wise to instruct the patient and have the pharmacist put on the label to eat a small snack or meal before each analgesic dosing. Codeine is a schedule II narcotic.

*Hydrocodone*

Hydrocodone is an opioid that is commonly compounded with acetaminophen for use for pain management, although it is available in a noncompounded form. It possesses the same cough suppressant and analgesic properties as codeine; however, owing to its heightened abuse potential has recently become more highly regulated by the inability for physicians to telephone or order refill prescriptions. Hydrocodone comes in 5-, 7.5-, and 10-mg formulations. The most common hydrocodone compound used for pain control by dentists is hydrocodone 5 mg and acetaminophen 300 mg. Hydrocodone is a schedule II narcotic.

*Oxycodone*

Oxycodone is an opioid and typically the most potent narcotic prescribed by dentists. It is available in both noncompounded and compounded forms. Compounded forms usually include aspirin or acetaminophen. The most commonly used oxycodone compound by dental professionals contains 5 mg of oxycodone and 325 mg of acetaminophen. Oxycodone has a very high abuse potential and a high value when sold illicitly. Therefore, caution should be exercised when considering prescribing this drug to patients. Oxycodone is a schedule II narcotic.

**Reference**

1. Hupp JR, Ellis III E, Tucker MR: Contemporary Oral And Maxillofacial Surgery (ed 6). St. Louis, MO, Elsevier, 2014